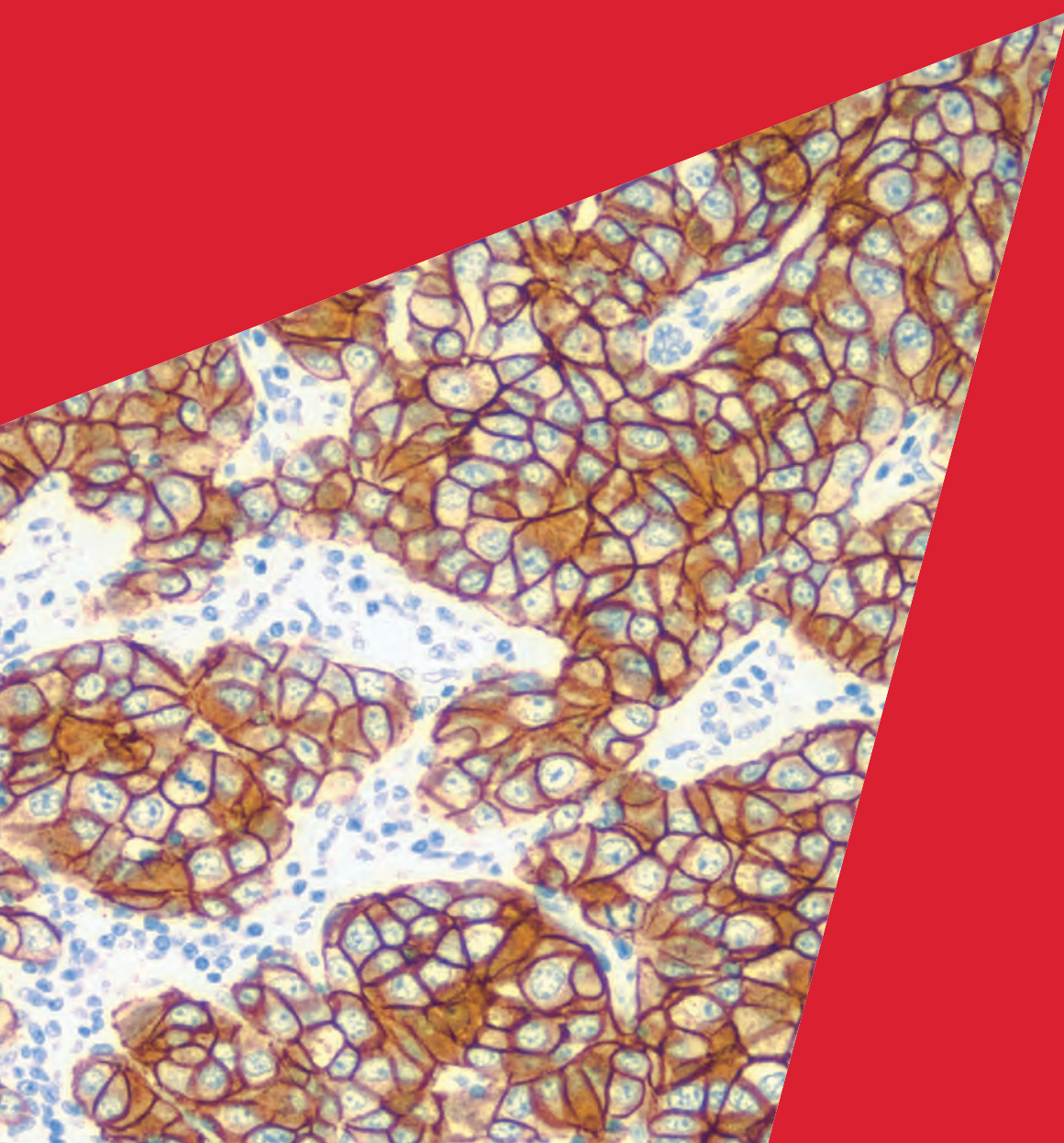


EDUCATION

HercepTest™

Interpretation Manual  
Breast Cancer



An Agilent Technologies Company

EDUCATION

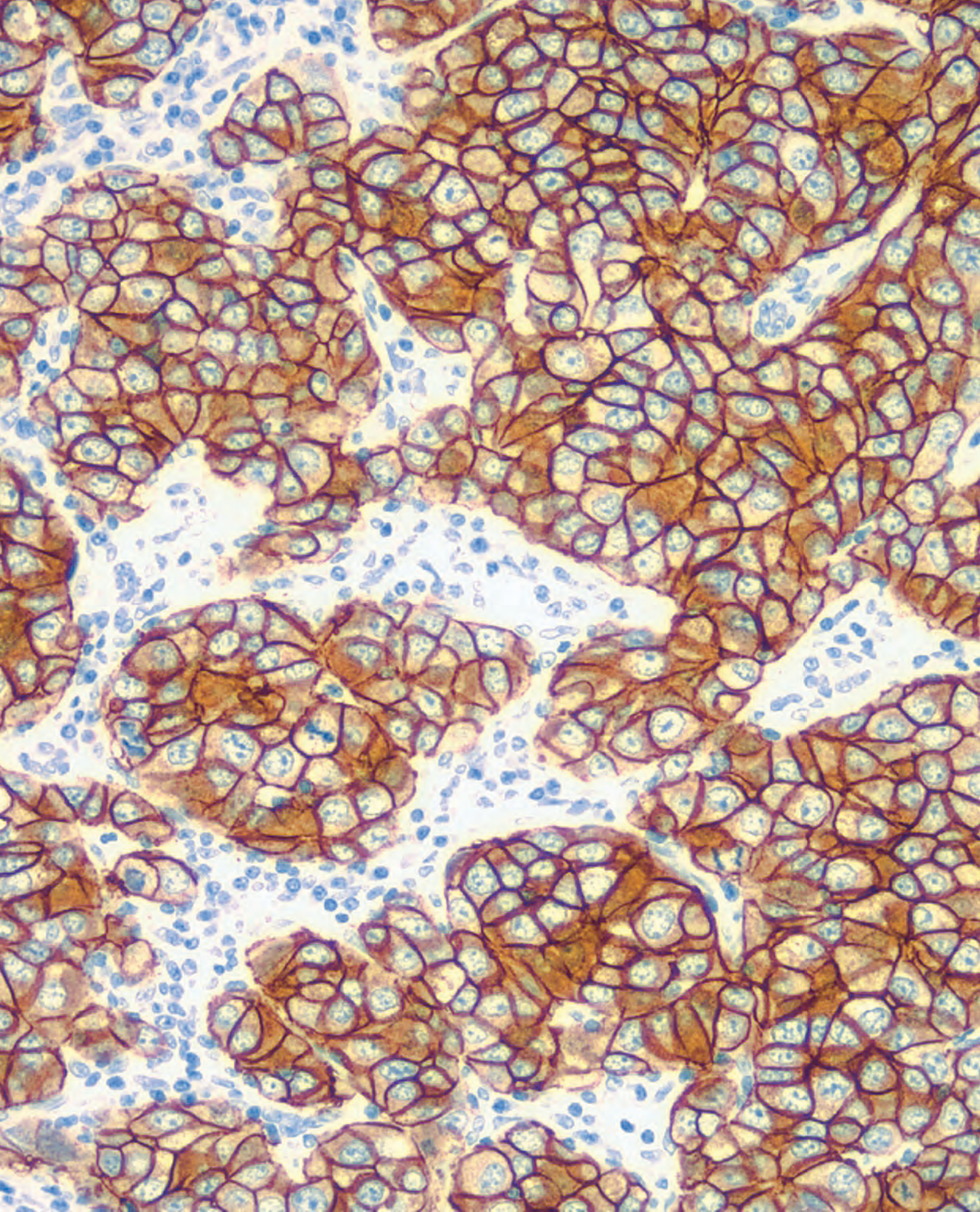
# HercepTest™ | Table of Contents



# Contents

<b>5</b>	<b>Introduction</b>
<b>6</b>	<b>HER2 Overview</b>
6	HER2 Protein and HER2 Family
6	HER2 Testing IHC and FISH
7	HER2 Testing Algorithm
8	The HercepTest™ Kit
<b>9</b>	<b>HER2 IQFISH pharmDx™ Kit</b>
9	Hybridizer Instrument for In Situ Hybridization (FISH)
<b>10</b>	<b>Checklist</b>
10	HercepTest™ Training Checklist
<b>11</b>	<b>Recommendations</b>
11	Recommended Data Tracking for HercepTest™ Immunostaining
<b>12</b>	<b>Technical Considerations</b>
12	Technical Considerations for Optimal HercepTest™ Performance
12	Protocol Recommendations
13	Tissue Processing Considerations
13	Tissue Processing Recommendations
<b>14</b>	<b>Guidelines</b>
14	Review of HercepTest™ Scoring Guidelines
14	Validation of the Assay
15	Interpretation Guide for 1+ Cell Line
16	Guidelines for Scoring
<b>17</b>	<b>Interpretation</b>
17	Recommendations for Interpretation of HercepTest™ – Breast Cancer
17	Steps for HercepTest™ Interpretation
<b>19</b>	<b>Staining Patterns</b>
<b>24</b>	<b>Artifacts</b>
24	Interpreting Artifacts
<b>28</b>	<b>Effects of Fixation</b>
<b>29</b>	<b>Effects of Insufficient Target Retrieval</b>
<b>30</b>	<b>Effects of Excessive Tissue Drying</b>
<b>31</b>	<b>Staining Images</b>
31	HER2 Expression in Various Diagnostic Entities
<b>46</b>	<b>Troubleshooting Guide</b>
46	Troubleshooting Guideline for HercepTest™
<b>49</b>	<b>Bibliography</b>







# Introduction

## HercepTest™ Interpretation Manual

HercepTest™ is a semi-quantitative immunohistochemical assay to determine HER2 protein overexpression in breast cancer tissues routinely processed for histological evaluation and formalin-fixed, paraffin-embedded cancer tissue from patients with adenocarcinoma of the stomach, including the gastroesophageal junction\*. HercepTest™ is indicated as an aid in the assessment of breast and gastric cancer patients for whom Herceptin® (trastuzumab) treatment is being considered (see Herceptin® package insert).

## HercepTest™ Interpretation Guidelines

Prior to HercepTest™, immunohistochemistry was practiced largely as a subjective method, ideally suited for qualitative analysis. HercepTest™, however, changed this paradigm, as the determination of positivity was no longer a simple yes or no answer. Patients are now evaluated using immunohistochemistry technology applied as a semi-quantitative tool with a scoring system reflective of intensity of staining in conjunction with percentage of stained tumor cells. This shift in application introduced a change in the way immunohistochemistry was viewed.

This HercepTest™ Interpretation Manual for breast cancer is provided as a tool to help guide pathologists and laboratorians to achieve correct and reproducible results.

The goal of this manual is to familiarize you with the requirements for scoring breast carcinomas stained with HercepTest™. Example cases of various staining intensities of HER2 expression are provided for reference. The HercepTest™ package insert guidelines will be reviewed and technical tips for ensuring high-quality staining in your laboratory will be given. Reviewing this HercepTest™ Interpretation Manual will provide a solid foundation for evaluating slides stained with HercepTest™.

Most metastatic breast cancer tissue specimens tested for HER2 overexpression are scored with either 0 or 3+ staining intensity. While the majority of cases are clear-cut, a small percentage of the remaining 1+ and 2+ scored samples may be more difficult to interpret. In this manual, we will focus on these equivocal samples. In addition, we will review images of sample artifacts and discuss how to best interpret such cases.

## HER2 IQFISH pharmDx™

Despite the high quality of HercepTest™, clinical response of weakly positive specimens has remained an area of uncertainty within HER2 assessment. *HER2* IQFISH pharmDx™ complements HercepTest™ by quantitatively determining HER2 gene amplification and clarifying equivocal cases. HercepTest™ and *HER2* IQFISH pharmDx™ enhance patient care by aiding in proper determination of the appropriate course of treatment.

## Photomicrographs

The included photomicrographs are breast carcinoma unless otherwise noted.

\* Van Cutsem E, Kang Y, Chung H, Shen L, Sawaki A, Lordick F, et al. Efficacy results from the ToGA trial: A phase III study of trastuzumab added to standard chemotherapy in first-line human epidermal growth factor receptor 2 positive advanced gastric cancer. *J Clin Oncol* 2009;27:18s, (suppl; abstr LBA2409). (<http://media.asco.org/silver>).

Dako is a registered trademark of Dako Denmark A/S. HercepTest™ and Herceptin® are trademarks owned by Genentech, Inc. and/or F. Hoffman-La Roche Ltd.; HercepTest™ is subject to an exclusive trademark license to Dako Denmark A/S.

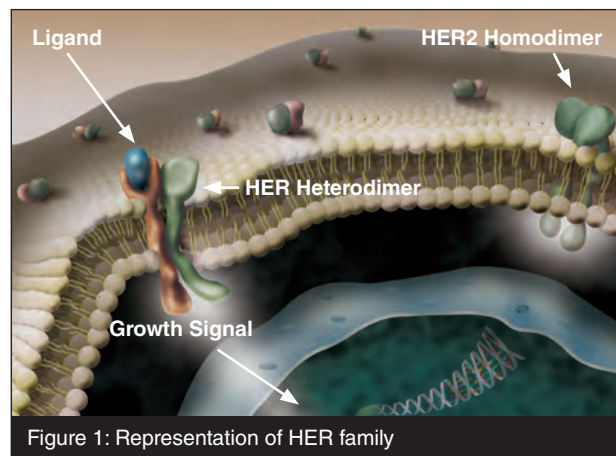
# HER2 Overview

## HER2 Protein and HER2 Family

The gene encoding HER2 is located on chromosome 17 and is a member of the EGF/erbB growth factor receptor gene family, which also includes epidermal growth factor receptor (EGFR, or HER1), HER3/erbB3 and HER4/erbB4. All of these genes encode transmembrane growth factor receptors, which are tyrosine kinase type 1 receptors with growth stimulating potential. Activation of HER family members generally occurs when the ligand and a dimer of the same monomer or other member of the HER family are bound together. HER2 has no known ligand. Once activation has occurred, tyrosine autophosphorylation of cytoplasmic signal proteins transmit signals to the nucleus, thus regulating aspects of cell growth, division, differentiation and migration.

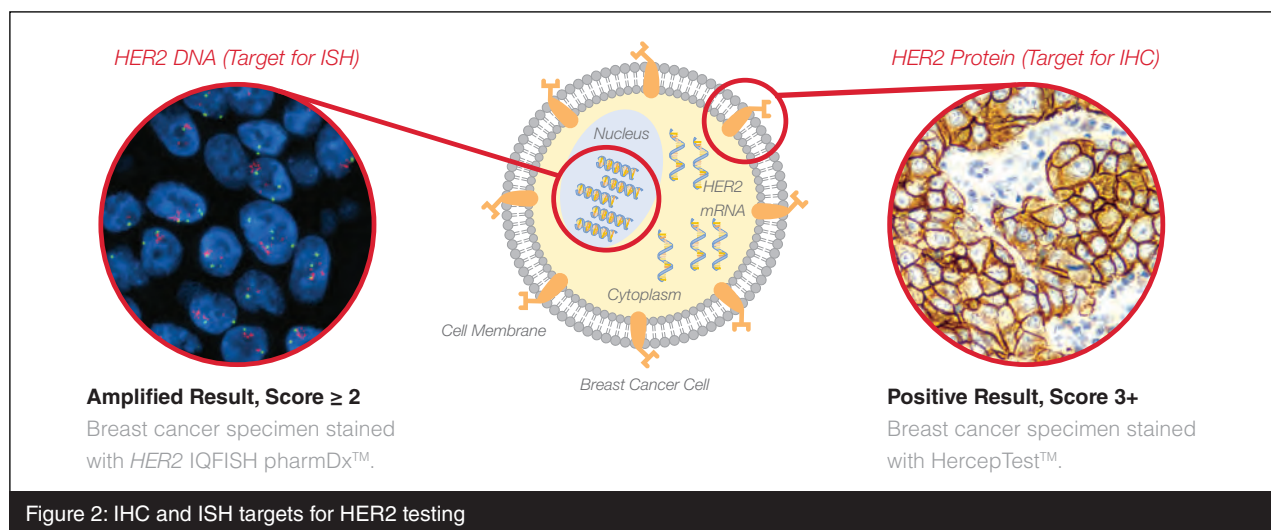
Overexpression of HER2 receptors results in receptors transmitting excessive signals for cell proliferation to the nucleus. This may lead to more aggressive growth of the transformed cell. Data supports the hypothesis that the HER2-overexpression cells directly contribute to the

pathogenesis and clinical aggressiveness of tumors.\* This overexpression is associated with poor prognosis, including reduced relapse-free and overall survival.



## HER2 Testing IHC and FISH

Immunohistochemistry (IHC) measures the level of HER2 receptor overexpression, while fluorescence in situ hybridization (FISH) quantifies the level of *HER2* gene amplification. Together they are the most commonly used methods of determining HER2 status in routine diagnostic settings.



\* Robert W. Carlson, MD; Susan J. Moench, et al. *HER2 Testing in Breast Cancer: NCCN Task Force Report and Recommendations: Journal of the National Comprehensive Cancer Network* July 2005. | Edith A. Perez, Vera J. Suman, et al. *HER2 Testing by Local, Central and Reference Laboratories in Specimens from the North Central Cancer Treatment Group N9831 Intergroup Adjuvant Trial. Journal of Clinical Oncology* July 1, 2006. | Martine J. Piccart-Gebhart, MD., Ph.D., Marion Proctor, M. Sci., et al. *Trastuzumab after Adjuvant Chemotherapy in HER2-Positive Breast Cancer. New England Journal of Medicine* October 20, 2005.

## HER2 Testing Algorithm

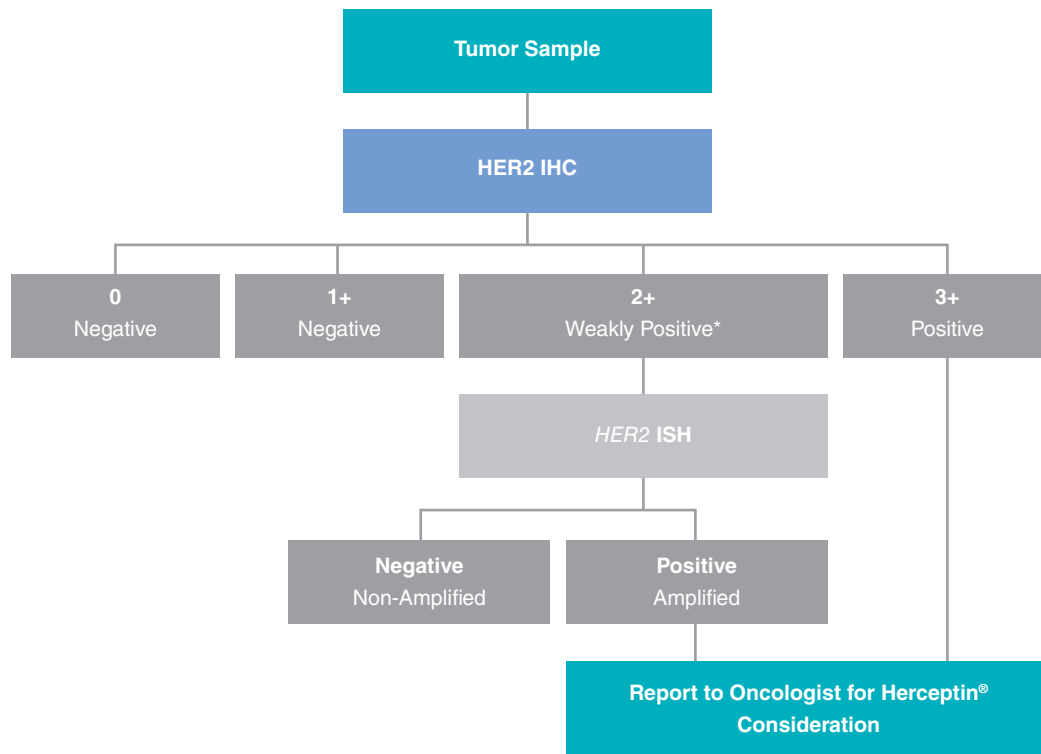


Figure 3: Current clinical practices for selection of patients for Herceptin® treatment.

\* For Herceptin® – Weakly positive cases (2+) may be considered equivocal and reflexed to ISH testing.

NCCN Practice Guidelines in Oncology, CAP Conference Summary Laboratories performing HER2 testing should meet quality assurance standards.

# The HercepTest™ Kit

HercepTest™ is a semi-quantitative immunohistochemical kit system for determination of HER2 protein overexpression in breast cancer tissues routinely processed for histological evaluation and in formalin-fixed, paraffin-embedded cancer tissue from patients with adenocarcinoma of the stomach, including gastro-esophageal junction.

Following incubation with the primary antibody to human HER2 protein, this kit employs a ready-to-use Visualization Reagent based on dextran technology. This reagent consists of both secondary goat anti-rabbit molecules and horseradish peroxidase molecules linked to a common dextran polymer backbone, thus eliminating the need for sequential application of link antibody and peroxidase conjugate. The enzymatic conversion of the subsequently added chromogen results in formation of a visible reaction product at the antigen site. The specimen may then be counterstained and coverslipped. Control cell line slides are provided.

HercepTest™ is a complete kit and includes:

- Peroxidase-Blocking Reagent
- Rabbit Anti-Human HER2 Protein
- Visualization Reagent

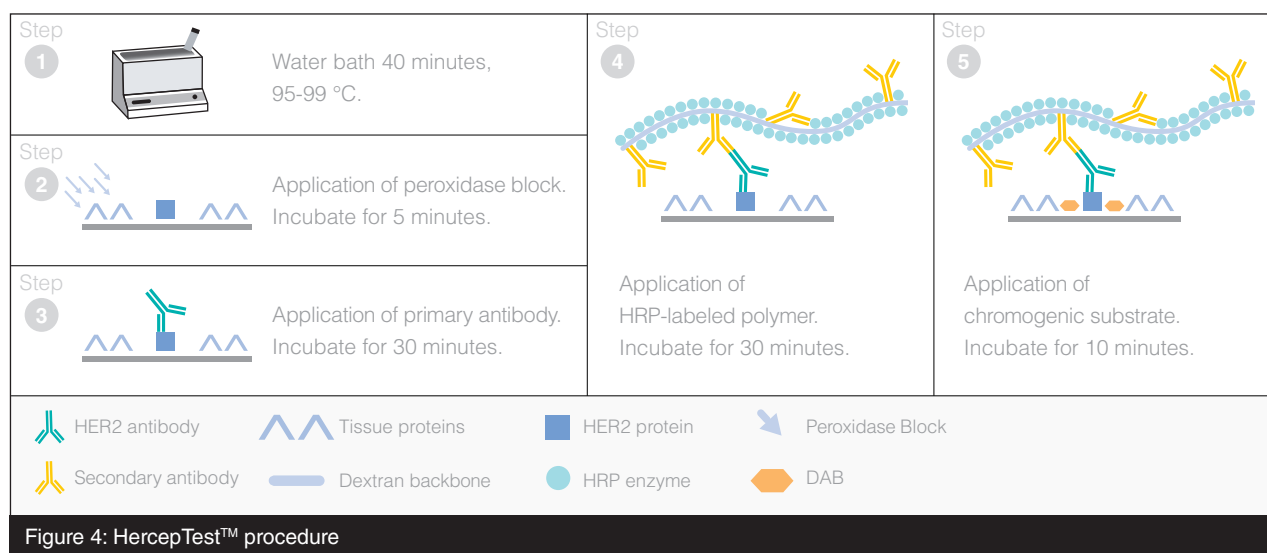
- Negative Control Reagent
- DAB Buffered Substrate
- DAB Chromogen
- Epitope Retrieval Solution (10x)
- Wash Buffer (10x) (not included in SK001)
- User-Fillable Bottles (only included in SK001)

Recommended hematoxylin counterstain:  
(not provided)

- Mayer's Hematoxylin for Dako Autostainer/ Autostainer Plus, Code S3301
- Mayer's Hematoxylin for Automated Link Platforms, Code SK308

Three HercepTest™ kit configurations are available:

<b>K5204</b>	<b>35 Tests</b>
HercepTest™ for manual use	
<b>K5207</b>	<b>50 Tests</b>
HercepTest™ for the Dako Autostainer	
<b>SK001</b>	<b>50 Tests</b>
HercepTest™ for Automated Link Platforms	





# HER2 IQFISH pharmDx™ Kit

HER2 IQFISH pharmDx™ kit is a direct fluorescence in situ hybridization (FISH) assay designed to quantitatively determine *HER2* gene amplification in formalin-fixed, paraffin-embedded (FFPE) breast cancer tissue specimens and FFPE specimens from patients with adenocarcinoma of the stomach, including gastroesophageal junction. *HER2* IQFISH pharmDx™ kit is indicated as an aid in the assessment of breast and gastric patients for whom Herceptin® (trastuzumab) treatment is being considered (see Herceptin® package insert).

For breast cancer patient, results from the *HER2* IQFISH pharmDx™ Kit are intended for use as an adjunct to the clinicopathologic information currently used for estimating prognosis in stage II, node-positive breast cancer patients.

The assays includes a chromosome 17 reference probe to correct for *HER2* signal number in the event of chromosome 17 aneusomy.

- CEN-17 PNA probes directly labeled with fluorescein (FITC) targets the centromeric region of the chromosome (green signals)
- *HER2* DNA probe directly labeled with Texas Red fluorochrome targets the *HER2* amplicon (red signals)
- Results are expressed as a ratio of *HER2* gene copies (red signals) per number of chromosome 17 copies (green signals)

HER2 IQFISH pharmDx™ is a complete kit and includes

- Pre-Treatment Solution 20x
- Pepsin, Ready-to-Use
- Pepsin Diluent (10x)
- *HER2*/CEN-17 IQISH Probe Mix
- Stringent Wash Buffer 20x
- Fluorescence Mounting Medium, containing DAPI
- Wash Buffer 20x
- Coverslip Sealant

## K5731

20 Tests

HER2 IQFISH pharmDx™ Kit  
(22 x 22 mm target area)

## Hybridizer Instrument for In Situ Hybridization (FISH)

Hybridizer is a hands-free, denaturation and hybridization instrument. The system allows for semi-automation of FISH by eliminating manual steps in the hands-on intensive manual procedure.

## S2450

Hybridizer

120 volt

## S2451

Hybridizer

240 volt



Figure 5: Dako Hybridizer instrument

# Checklist

## HercepTest™ Training Checklist

Customer Name/Institution \_\_\_\_\_

Person Trained/Title \_\_\_\_\_

Manual Staining Run ☐ Yes ☐ No If no, complete the information below.

Dako Autostainer Software Version \_\_\_\_\_ Dako Autostainer Serial Number \_\_\_\_\_

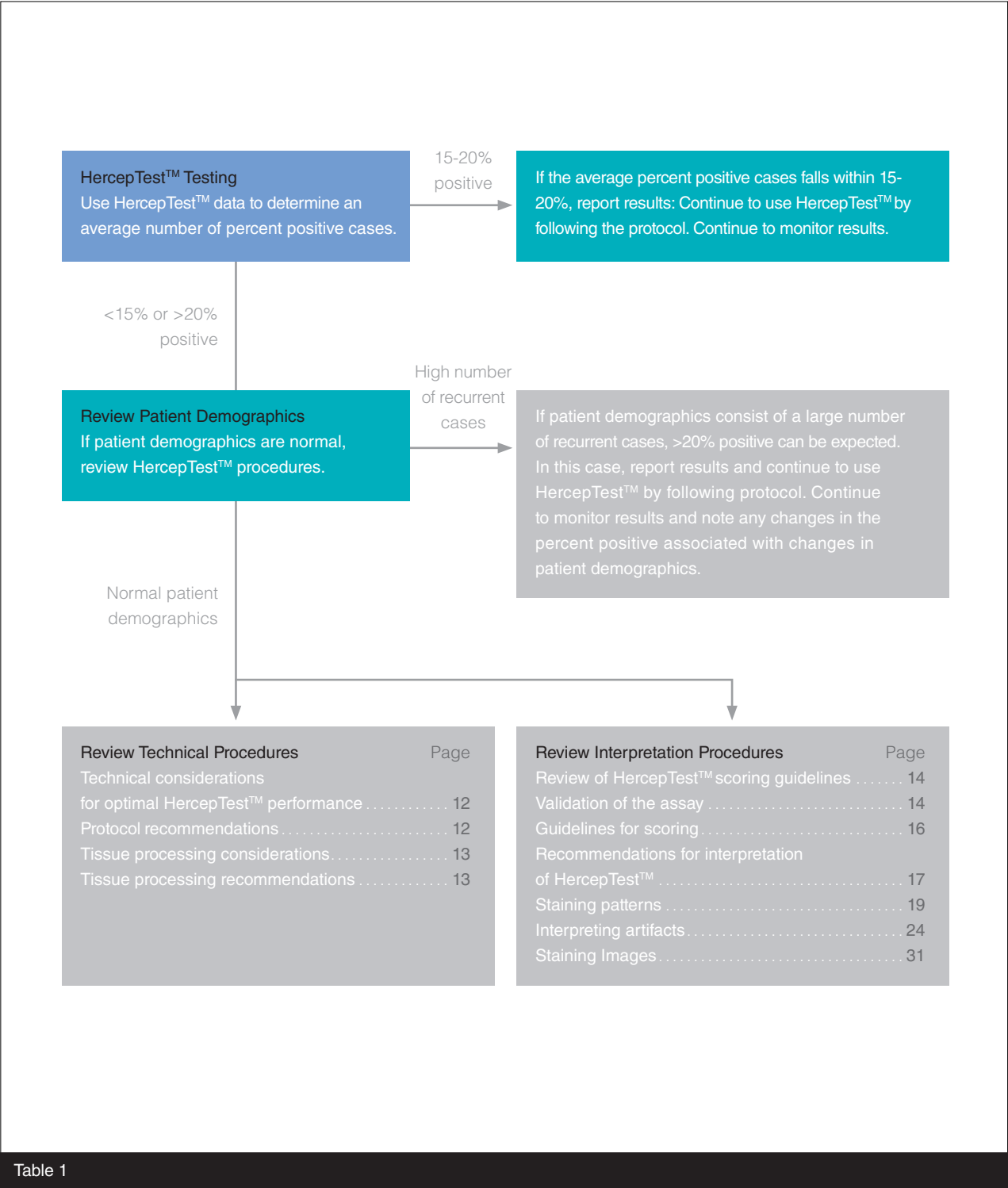
Dako Automated Link Platform Software Version \_\_\_\_\_ Dako Automated Link Platform Serial Number \_\_\_\_\_

### Manual, Dako Autostainer or Automated Link Platform Procedure

	Yes	No		Yes	No
Control slides and kit stored at 2–8 °C?	<input type="checkbox"/>	<input type="checkbox"/>	Specimens fully covered for 30 minutes with three drops (100 µl) of Primary Antibody or Negative Control Reagent?	<input type="checkbox"/>	<input type="checkbox"/>
Cell Line control slides and all reagents warmed to room temperature (20-25 °C) prior to starting assay?	<input type="checkbox"/>	<input type="checkbox"/>	Visualization Reagent applied for 30 minutes and specimen fully covered?	<input type="checkbox"/>	<input type="checkbox"/>
Tissues fixed in 10% neutral buffered formalin or Bouin's fixative only?	<input type="checkbox"/>	<input type="checkbox"/>	Substrate-Chromogen (DAB) Solution prepared properly? Mix 1 drop of DAB Chromogen with 1 mL DAB Buffered Substrate.	<input type="checkbox"/>	<input type="checkbox"/>
Specimens air-dried at room temperature for a minimum of 12 hours (or until dry) or at 37 °C overnight or at 60 °C for one hour?	<input type="checkbox"/>	<input type="checkbox"/>	Substrate-Chromogen solution applied for 10 minutes and specimen fully covered?	<input type="checkbox"/>	<input type="checkbox"/>
Specimens stained within 4-6 weeks of tissue mounted on slides when stored at room temperature?	<input type="checkbox"/>	<input type="checkbox"/>	<b>Dako Autostainer or Automated Link Platform Procedure</b>		
Clearing solutions changed after 40 slides?	<input type="checkbox"/>	<input type="checkbox"/>	Slides placed in buffer 5 (±1) minutes before loading onto the Dako Autostainer?	<input type="checkbox"/>	<input type="checkbox"/>
Deparaffinization and rehydration protocol followed?	<input type="checkbox"/>	<input type="checkbox"/>	Appropriate protocol template used?	<input type="checkbox"/>	<input type="checkbox"/>
Wash Buffer prepared properly? Prepare sufficient quantity of Wash Buffer by diluting Wash Buffer 10X, 1:10 in Reagent Quality Water (deionized or distilled water).	<input type="checkbox"/>	<input type="checkbox"/>	For each slide, is 200 µl of Primary Antibody or Negative Control Reagent applied?	<input type="checkbox"/>	<input type="checkbox"/>
Distilled or deionized water (not tap water) used for water washes after last alcohol bath in deparaffinization?	<input type="checkbox"/>	<input type="checkbox"/>	Was the Dako Autostainer/Automated Link Platform programming reviewed for accuracy?	<input type="checkbox"/>	<input type="checkbox"/>
Water bath used and set to proper temperature (95-99 °C)?	<input type="checkbox"/>	<input type="checkbox"/>	Slides rinsed with buffer between steps and double rinsed after the Visualization Reagent step?	<input type="checkbox"/>	<input type="checkbox"/>
Epitope Retrieval Solution brought to 95 °C after slides immersed, before 40 minutes incubation started?	<input type="checkbox"/>	<input type="checkbox"/>	Substrate-Chromogen (DAB) Solution prepared properly? Dako Autostainer: Add 11 drops of DAB Chromogen to one vial of DAB Buffered Substrate.	<input type="checkbox"/>	<input type="checkbox"/>
Slides allowed to cool for 20 minutes in Epitope Retrieval Solution?	<input type="checkbox"/>	<input type="checkbox"/>	Dako Automated Link Platform: Mix an appropriate amount of DAB Buffered Substrate with 25 µL DAB Chromogen per mL DAB Buffered Substrate.		
Either alcohol or water-based hematoxylin counterstains used?	<input type="checkbox"/>	<input type="checkbox"/>	Substrate-Chromogen Solution (DAB) applied for 10 minutes?	<input type="checkbox"/>	<input type="checkbox"/>
<b>Manual Procedure</b>			<b>Instrumentation / Equipment</b>		
Distilled or deionized water (not tap water) used for water bath after Substrate-Chromogen Solution (DAB) step?	<input type="checkbox"/>	<input type="checkbox"/>	Is regular preventative maintenance performed on the Dako Autostainer/Automated Link Platform?	<input type="checkbox"/>	<input type="checkbox"/>
Diluted Wash Buffer used for all wash steps and baths (after Peroxidase-Block, Primary Antibody/Negative Control Reagent, Visualization Reagent)?	<input type="checkbox"/>	<input type="checkbox"/>	Do you have all the necessary equipment to perform the HercepTest assay according to protocol? If not, specify what is missing in comments below.	<input type="checkbox"/>	<input type="checkbox"/>
Buffer bath(s) changed between each step? Humid chamber used for Primary Antibody/ Negative Control Reagent/Visualization Reagent incubations?	<input type="checkbox"/>	<input type="checkbox"/>	If you answered "No" to any of the above, you have deviated from protocol and should consult with your local Dako Technical Support Representative for assistance.	<input type="checkbox"/>	<input type="checkbox"/>
Slides placed in 5 (±1) minute buffer baths between Peroxidase Block, Primary Antibody/ Negative Control Reagent, Visualization Reagent and Substrate-Chromogen Solution (DAB) steps?	<input type="checkbox"/>	<input type="checkbox"/>	Additional observations or comments:	_____	
Peroxidase-Blocking Reagent applied for five minutes and specimen fully covered?	<input type="checkbox"/>	<input type="checkbox"/>		_____	
				_____	

# Recommendations

## Recommended Data Tracking for HercepTest™ Immunostaining





# Technical Considerations

## Technical Considerations for Optimal HercepTest™ Performance

While accurate and consistent interpretation can be achieved, technical issues relating to the performance of HercepTest™ are not always easy to identify. If cumulative laboratory test results fall outside the expected range of 15-20% positive, evaluate the patient demographics and then address any technical problems.

Technical problems may arise in two areas, those involving sample collection and preparation prior to performing the test, and those involving the actual performance of the test itself. Technical problems relating to the performance of the test generally are related to procedural deviations and can be controlled and eliminated through training and, where necessary, clarification of the product instructions.

## Protocol Recommendations

### Pre-treatment Using Water Bath

#### Water Bath:

Heat HercepTest™ Epitope Retrieval Solution in a calibrated water bath capable of maintaining the required temperature of 95-99 °C. For best results, fill a container suitable for holding slides with diluted epitope retrieval (1:10) solution. Place container with epitope retrieval solution in a water bath and bring the temperature of the water bath and the epitope retrieval solution to 95-99 °C. Add the tissue sections mounted on slides to the container and bring the temperature of the epitope retrieval solution back to 95 °C before starting the timer.

#### Incubation Time:

Incubate the slides for 40 (±1) minutes in the preheated epitope retrieval solution. Remove the container with the slides from the water bath, but keep them in the epitope retrieval solution while allowing them to cool for 20 (±1) minutes at room temperature. After cooling, decant the epitope retrieval solution and rinse in wash buffer. For optimal

performance, soak sections in wash buffer for 5-20 minutes after epitope retrieval and prior to staining.

### Pre-treatment Using PT Link

Preheat the diluted epitope retrieval solution (1:10) in the Dako PT Link tank to 85 °C. Place the room temperature, deparaffinized sections in Autostainer racks and immerse the slides into the preheated epitope retrieval solution. Let the PT Link warm up to 97 °C and incubate for 40 (±1) minutes at 97 °C. Leave the sections to cool in the PT Link until the temperature reaches 85 °C. Remove the PT Link tanks with the sections from the PT Link and leave the tanks on the table for 10 minutes with the lid off for further cooling. Prepare a jar/tank, eg. the PT Link Rinse Station, with diluted Dako Wash Buffer and soak sections for 5-20 minutes after epitope retrieval and prior to staining. Dedicated PT Link equipment must be used for HercepTest™.

### Proper Incubations

All incubation times should be performed according to the package insert. Stay within ±1 minute of all incubation times. If staining must be interrupted, slides may be kept in wash buffer following incubation of the primary antibody for up to one hour at room temperature (20-25 °C).

### Automated Staining

Dako recommends the use of HercepTest™ on an Autostainer Link or a Dako Autostainer. Use of HercepTest™ on alternative automated platforms has not been validated and may give erroneous results.

### **Wash Buffer**

Dilute the recommended wash buffer 1:10 using distilled or deionized water. Store unused diluted solution at 2-8 °C up to one month. Discard diluted, solution if cloudy in appearance.

### **Storage of Reagents**

Reagents should be stored at 2-8 °C. Do not use after the expiration date stamped on the outside package.

## **Tissue Processing Considerations**

Procedural deviations related to sample handling and processing can affect HercepTest™ results.

Some of the variables that affect outcome are as follows:

- Specimens drying prior to fixation
- Type of fixative; only neutral buffered formalin is recommended
- Temperature, age, storage, pH of fixative
- Length of fixation, specimen size, ratio of size to fixative volume
- Length of time in alcohol after primary fixation
- Processing time, temperature pressure, and chemicals used
- Storage of paraffin blocks
- Storage of cut sections
- Section thickness

## **Tissue Processing Recommendations**

### **Validated Fixatives**

- Neutral Buffered Formalin
- Bouin's Solution

### **Fixation Times**

Neutral Buffered Formalin:

- 18-24 hours

Time to fixation and duration of fixation, if available, should be recorded for each sample.

Bouin's:

- 1-12 hours depending on tissue thickness

Tissues fixed in Bouin's solution must be washed in 70% ethanol to remove picrates prior to aqueous washes. Bouin's solution may not be optimal, if FISH testing is needed.

### **Specimen Thickness**

Tissue samples submitted for processing and embedding should not exceed 3-4 mm in thickness.

### **Processing and Embedding**

After fixation, tissues are dehydrated in a series of alcohols and xylene followed by infiltration by melted paraffin held at no more than 60 °C. Properly fixed and embedded tissues expressing the HER2 protein will keep indefinitely prior to sectioning and slide mounting if stored in a cool place, 15-25 °C. Overheating of tissues during embedding or overheating of sections during drying can induce detrimental effects on immunostaining and, therefore, should be avoided.

The slides required for HER2 protein evaluation and tumor presence should be prepared at the same time. To preserve antigenicity, tissue sections, mounted on slides, should be stained within four-to-six weeks of sectioning when held at room temperature, 20-25 °C. Tissue specimens should be cut into sections of 4-5 µm thickness.

To achieve reproducible results, each laboratory performing HercepTest™ should monitor its rate of positivity. If the positive rate exceeds 20%, a complete review of interpretation and technical procedures should be done.

# Guidelines

## Review of HercepTest™ Scoring Guidelines for Breast Tissue

HercepTest™ is a semi-quantitative immunohistochemical assay to determine HER2 protein overexpression in breast cancer tissues routinely processed for histological evaluation.

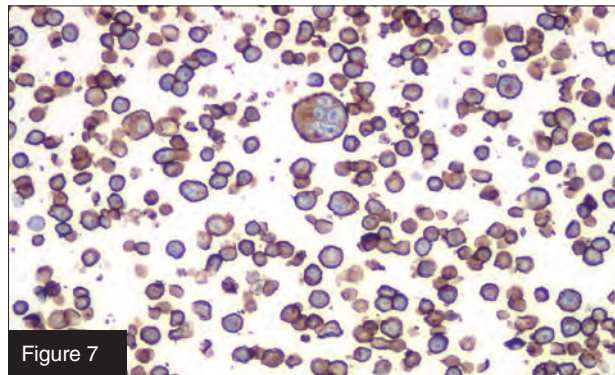
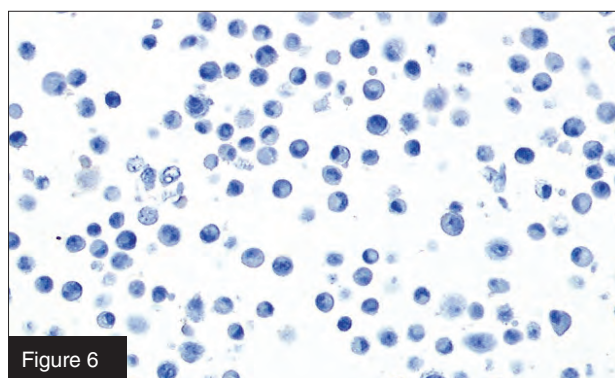
For the determination of HER2 protein overexpression, only the membrane staining intensity and pattern should be evaluated using the scale presented on page 16. Slide evaluation should be performed using a light microscope.

Verify that the negative tissue control slide from the same staining run demonstrates no reactivity.

## Validation of the Assay

Included in each HercepTest™ kit are control slides representing different levels of HER2 protein expression: MDA-231(0), MDA-175 (1+) and SK-BR-3 (3+). The first step of interpretation is to evaluate the control cell lines. The control cell lines have been provided for qualifying the procedure and reagents, not as an interpretation reference. No staining of the 0 control cell line, MDA-231, partial brown membrane rimming in the 1+ control cell line, MDA-175, (refer to the Interpretation Guide for 1+ Cell Line on next page), and presence of complete intense brown membrane staining (rimming) in the 3+ control cell line, SK-BR-3, indicates a valid assay. If any of the control cell lines perform outside of these criteria, all results with the patient specimens should be considered invalid.

Next, the positive tissue control slide known to contain the HER2 antigen, stained with HercepTest™ and fixed and processed similarly to the patient slides, should be evaluated for indication of correctly prepared tissues and proper staining technique. The ideal positive tissue control is weakly positive staining tissue. The presence of a brown reaction product at the cell membrane is indicative of positive reactivity.



**Figure 6:** 0 control cell line, MDA-231, stained with HercepTest™. No staining of the membrane is observed. (20x magnification).

**Figure 7:** 3+ control cell line, SK-BR-3, stained with HercepTest™. A strong staining of the entire membrane is observed. (20x magnification).



## Interpretation Guide for 1+ Cell Line

The 1+ control cell line can display different categories of HER2-specific cellular staining. Cells displaying a partial brown membrane rimming, where the immunostaining is punctate and discontinuous (Fig. 8, 1a), are the true indicators of a valid staining run. In some cells, the partial brown membrane rimming is more borderline (but still considered positive) consisting of a punctate and discontinuous immunostaining of both membrane and cytoplasm (Fig. 8, 1b). The borderline cells depicted here may reflect the difference in quality between images and true microscopy. In a normal IHC staining run of the 1+ control cell line, few cells will display a circumferential brown cell membrane staining (Fig. 8, 2). In addition, in some cells dot-like immunostaining can be observed in the Golgi region of the cytoplasm (Fig. 8, 3).

The different categories of HER2-specific cellular stainings may be reflected in the different appearances of acceptable 1+ cellular staining runs, e.g. low (Fig. 9) and moderate (Fig. 10).

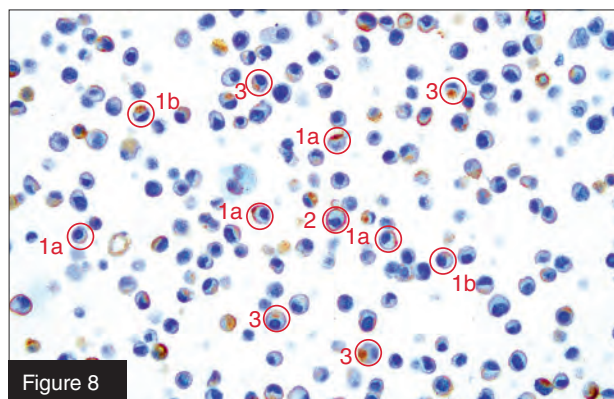


Figure 8

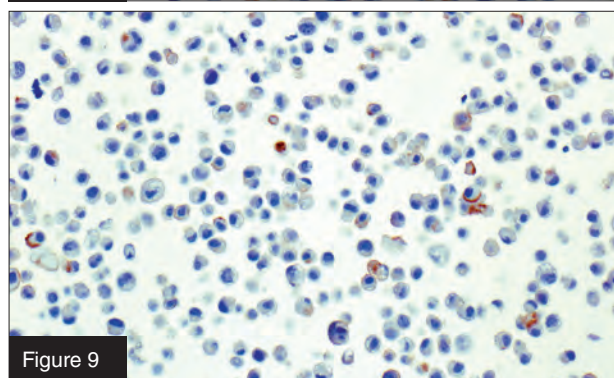


Figure 9

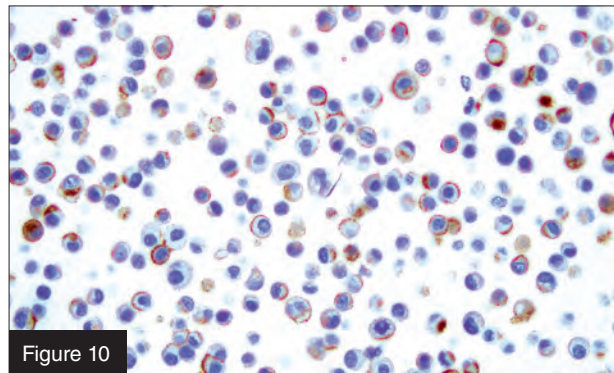


Figure 10

**Figure 8:** The 1+ control cell line, MDA-175 (20x), may display different categories of HER2-specific cellular stainings. Only the HER2 specific staining displayed as a partial brown membrane rimming – is used to validate the staining run. *Note: The image only represents approximately 50% of a 20x microscope visual field.*

**Figure 9:** 1+ control cell line, MDA-175 (20x), acceptable staining run with punctate and discontinuous membrane staining in a small number of cells. The “low-limit appearance” may reflect the difference in quality between images and true microscopy. *Note: The image only represents approximately 50% of a 20x microscope visual field.*

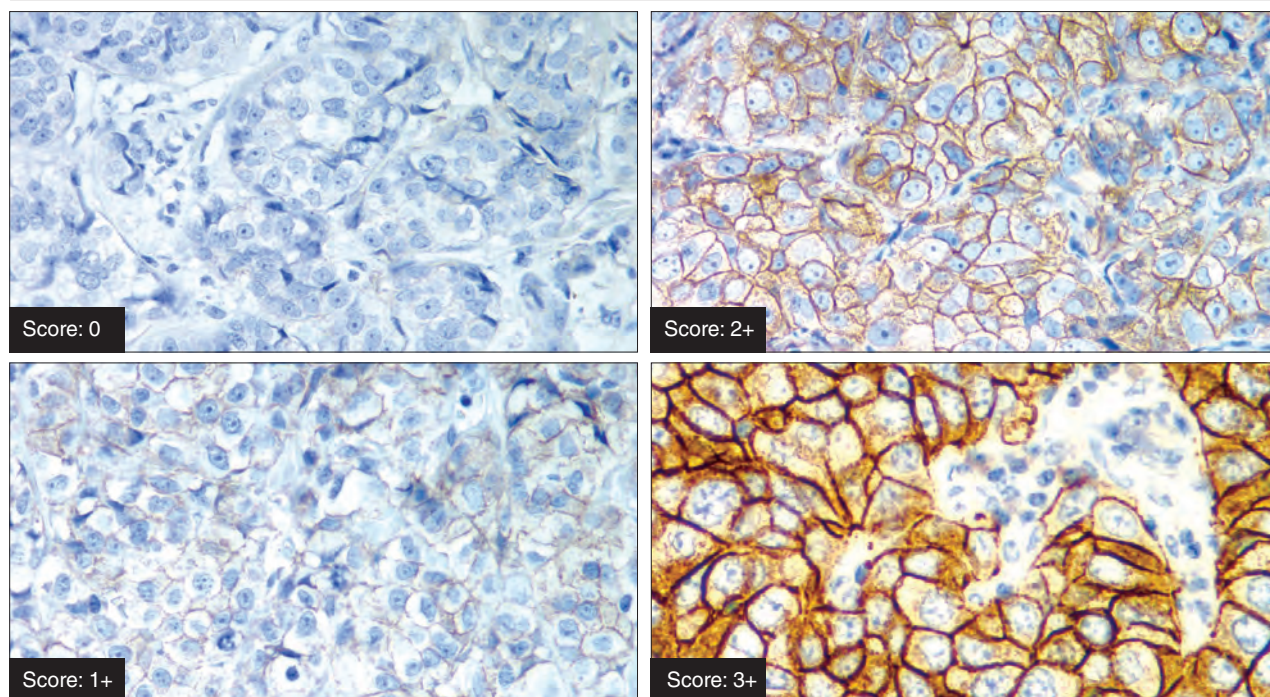
**Figure 10:** 1+ control cell line, MDA-175 (20x), acceptable staining run with punctate and discontinuous membrane staining in a moderate number of cells. *Note: The image only represents approximately 50% of a 20x microscope visual field.*

## Guidelines for Scoring

Use of the attached scoring system has proved reproducible both within and among laboratories. Dako recommends that scoring always be performed within the context of the pathologist's past experience and best judgment in interpreting IHC stains. Only

patients with invasive breast carcinoma should be scored. In cases with carcinoma in situ and invasive carcinoma in the same specimen, only the invasive component should be scored. Figure 9 shows examples of staining patterns.

Score to Report	HER2 Protein Overexpression Assessment	Staining Pattern
0	Negative	No staining is observed, or membrane staining is observed in <10% of the tumor cells.
1+	Negative	A faint/barely perceptible membrane staining is detected in >10% of tumor cells. The cells exhibit incomplete membrane staining.
2+	Weakly Positive*	A weak to moderate complete membrane staining is observed in >10% of tumor cells.
3+	Positive	A strong complete membrane staining is observed in >10% of tumor cells.



**Figure 11:** Examples of staining patterns for tissue scored 0, 1+, 2+, and 3+, at (40x magnification).

\* Weakly positive cases (2+): may be considered equivocal and reflexed to ISH testing.

# Interpretation

## Recommendations for Interpretation of HercepTest™ – Breast Cancer

Dako emphasizes that scoring of HercepTest™ must be performed in accordance with the guidelines established in the package insert and within the context of best practices and the pathologist's experience and best medical judgment. This manual will highlight areas of interpretation potentially problematic for HercepTest™ users.

The original Immunohistochemical assay (CTA) used by Genentech for the Herceptin® clinical trials utilized a scoring system later adopted by Dako as an integrated part of HercepTest™.

## Steps for HercepTest™ Interpretation

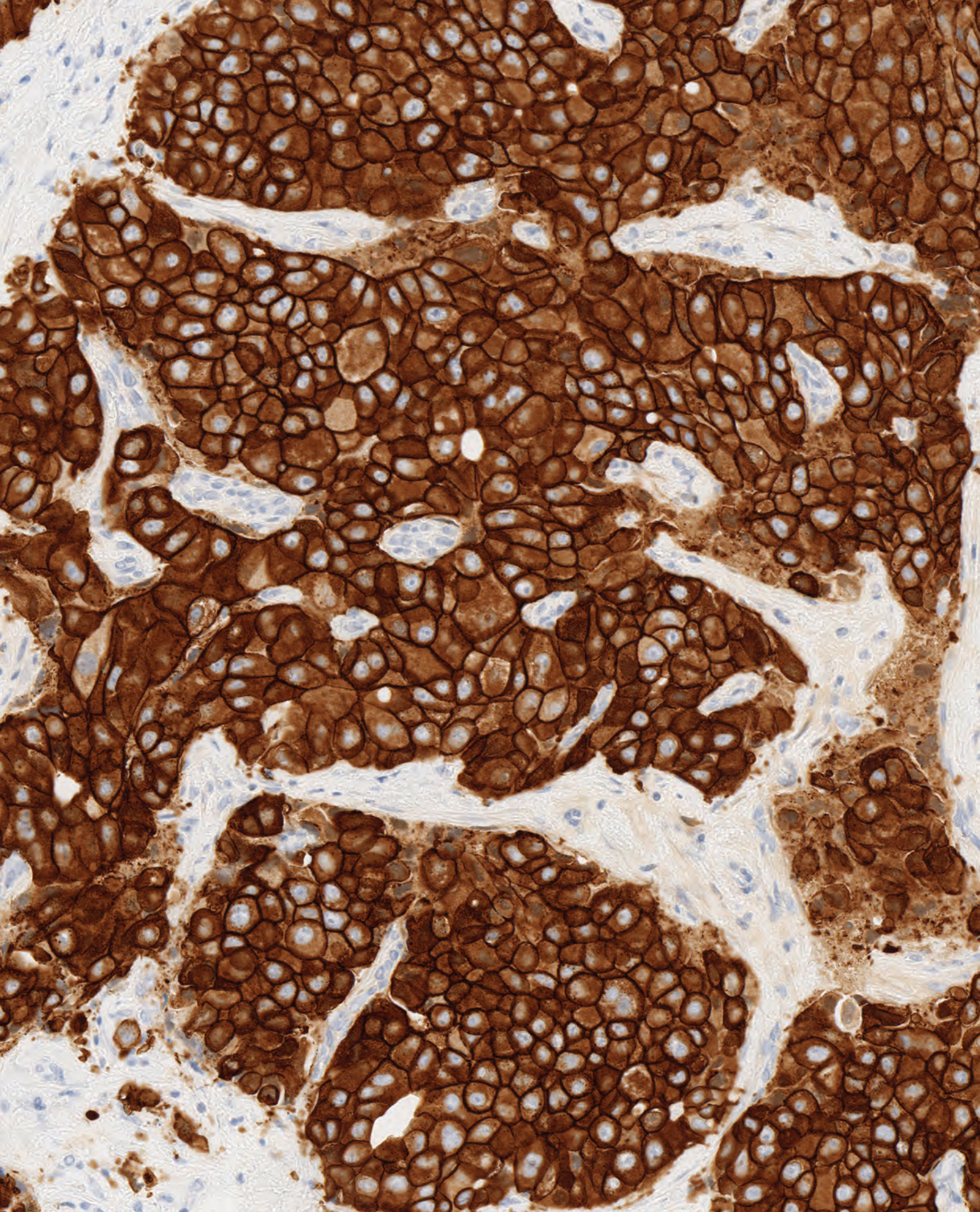
### Manual or Automated Interpretation

- 1 Evaluate the control cell lines to validate the assay run.
- 2 Next, evaluate the positive and negative control slides.
- 3 An H&E stained section of the tissue sample is recommended for the first evaluation. (The tumor may not be obvious when looking at the sample stained with HercepTest™. An H&E stain allows the pathologist to verify the presence of the invasive tumor).
- 2 To verify the percentage of stained tumor cells and completeness of membrane staining, use 10x magnification. Well-preserved and well-stained areas of the specimen should be used to make a determination of the percent of positive infiltrating tumor cells.
- 3 If determination of equivocal 1+/2+ cases is difficult using 10x magnification, confirm score using 20x or 40x magnification.
- 4 If there is complete membrane staining at a weak to moderate intensity in greater than 10% of the tumor cells, the score of the specimens is 2+. This is usually accompanied by incomplete membrane staining of the majority of the remaining tumor cells.
- 5 In the majority of 3+ cases, staining is usually homogeneous with approximately 80% of the tumor cells positive with intense membrane staining.

### Manual Interpretation with Conventional Microscopy

- 1 Evaluate the HER2 sections for estimation of the percentage of tumor cells showing membrane staining at low power first, 4x magnification. The majority of strongly positive cases will be obvious at 4x magnification. Invasive (infiltrating) breast cancer tumor cells are the only component that should be scored. In situ breast cancer cells should not be scored.







# Staining Patterns

## Heterogeneous Staining

Heterogeneous staining patterns occur less frequently as true biological entities. Consequently, when present, this staining pattern may represent artifacts of tissue preparation.

- The pathologist's experience and judgment is important in the evaluation of heterogeneous staining.
- Review these cases at a low power on the microscope.
- If the staining pattern is an artifact, the best representative area(s) should be graded. There must be >10% of the infiltrative tumor cells demonstrating complete membrane staining for the score to be at least 2+ or greater.
- In the absence of clear evidence for biological heterogeneity, the best representative area(s) should be scored, as long as >10% of the infiltrative tumor cells in these areas demonstrate complete membrane staining at a moderate to strong intensity. Focus on the most well-preserved and well-stained areas to make the determination.

## Focal Staining

Focal staining is usually 1+. Focal staining usually occurs in <10% of tumor cells and the score is, therefore, no greater than 1+. By definition, focal staining implies that most of the tumor cells are not stained or are stained only partially on their membranes. However, it is important to verify that fewer than 10% of the tumor cells demonstrate complete membrane staining.

## Staining not Associated with Tumor Cells

Occasionally, HER2 staining can be observed as luminal secretions of normal breast epithelium or may be seen as extracellular accumulations within the tissue. This staining pattern should be disregarded.

## DCIS Cases

HercepTest™ has no indication for ductal carcinoma in situ (DCIS) at this time. Staining of DCIS should be disregarded.

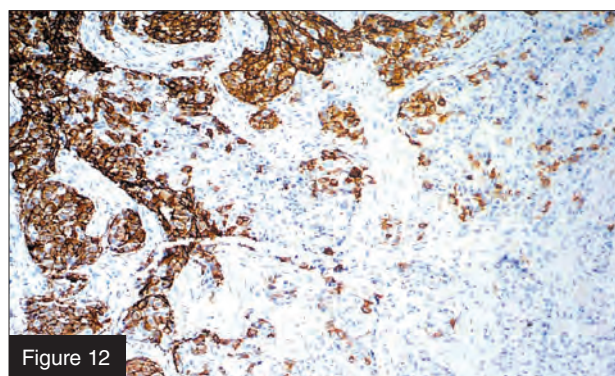


Figure 12

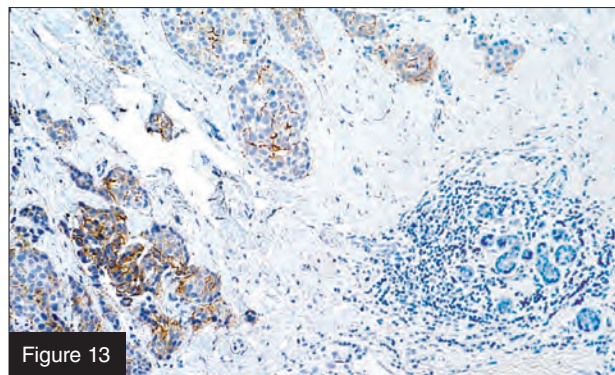


Figure 13

**Figure 12:** Breast carcinoma with example of heterogeneous staining. Characteristic feature: 3+ score on the left and 0 score on the lower right, with an intermingling of tumor cell subsets in between (>10% of the infiltrative tumor cells demonstrate complete membrane staining). (4x magnification).

**Figure 13:** Breast carcinoma with example of heterogeneous staining. Characteristic feature: 2+ score on lower left, 1+ score on upper middle, and negative on normal tissue on lower right. (4x magnification).

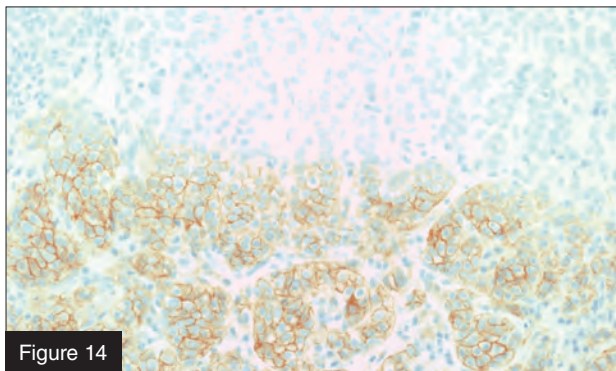


Figure 14

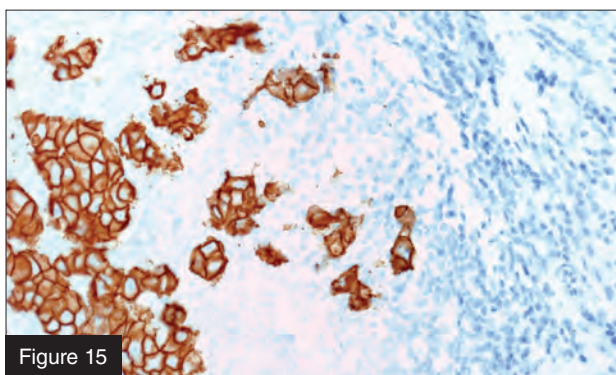


Figure 15

### Artificial Heterogeneous Staining

Heterogeneous staining may occur as a consequence of suboptimal performance of the immunohistochemical test.

- Incomplete spreading of reagent

**Figure 14:** Breast carcinoma with example of heterogeneous staining due to incomplete spreading of reagent. Characteristic feature: 3+ score on the lower part and 0 score on the upper. (10x magnification).

**Figure 15:** Breast carcinoma with example of heterogeneous staining due to incomplete spreading of hematoxylin. Characteristic feature: Weak counterstain to the left, appropriate counterstain to the right. (10x magnification).



## Background Staining

Background staining is defined as diffuse, non-specific staining of a specimen. It is caused by several factors. These factors include, but are not limited to, pre-analytic fixation and processing of the specimen, incomplete removal of paraffin from sections, and incomplete rinsing of slides.

The use of fixatives other than Neutral Buffered Formalin or Bouin's solution may be a source of background staining. Background staining with HercepTest™ is rare. This artifact may occur in 2-3% of cases. Background has been reported in breast tissues with abundant hyalinized stroma.

### Possible Cause of Background

- Improper drying of slides (use a humid chamber for primary antibody/negative control and labeled polymer HRP reagent incubations when the assay is performed manually)
- Improper deparaffinization procedure
- Use of a different wash buffer than recommended (Code S3006 is recommended)
- Incomplete rinsing of reagents from slides

The non-specific background staining of the negative test specimen is useful in ascertaining the level of background staining in the positive test specimen. If background staining is significant, the specific staining must be interpreted with caution.

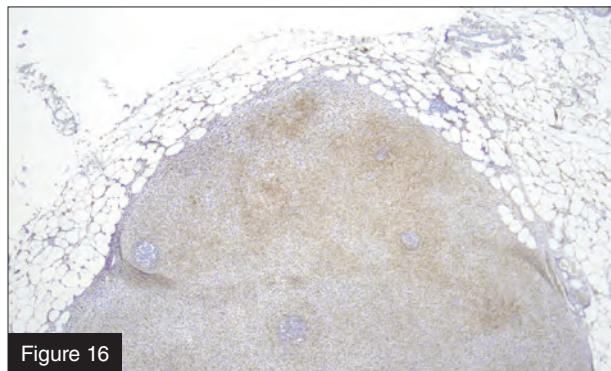


Figure 16

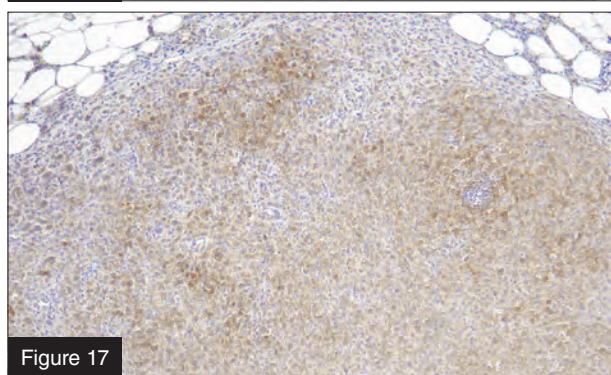


Figure 17

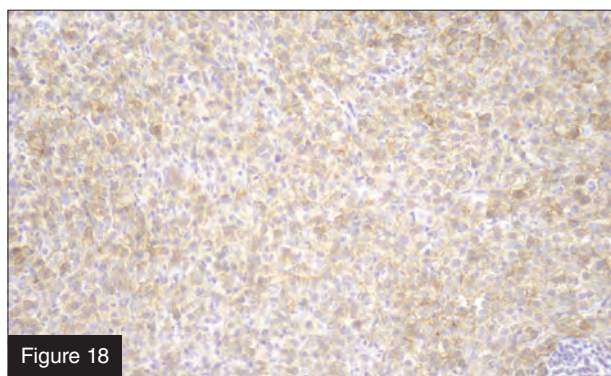


Figure 18

### Example of high, non-specific background. Score: 0

Characteristic feature: Diffuse smudgy brown stain in background stroma and cells.

**Figure 16:** Breast carcinoma, brown staining is apparent. (4x magnification).

**Figure 17:** Breast carcinoma, diffuse non-specific background staining can be seen. (10x magnification).

**Figure 18:** Breast carcinoma, minimal membrane staining is seen. 0 score is apparent. (20x magnification).

## Homogeneous Staining

Properly fixed breast cancer tissue with HER2 protein overexpression should reveal relative uniformity of immunostaining in individual tumor cells. In cases where variability in fixation of the tissue is present, the tissue may not appear homogeneous.

- In the majority of cases, breast tumor specimens stain homogeneously for HER2.
- Evaluation of homogeneous staining should be based on an overall (average) of all the infiltrative tumor cells. Review average staining of the whole section.
- Carefully evaluate:
  - The percent of infiltrative tumor cells showing complete membrane staining.
  - The intensity of staining:
    - If >10% of the infiltrative tumor cells exhibit complete membrane staining and there is a moderate intensity of staining, the score would be at least 2+.
    - If it is difficult to determine whether >10% of the infiltrative tumor cells show complete membrane staining, the score should be no greater than 1+.

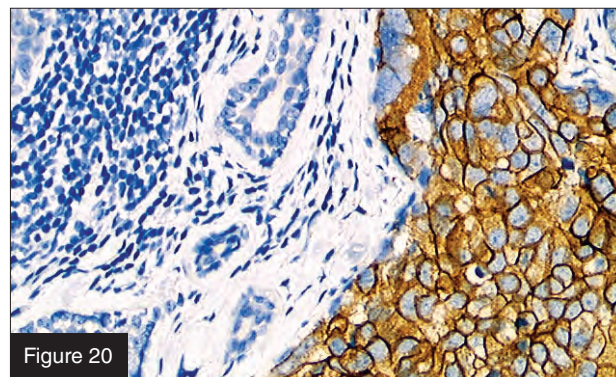
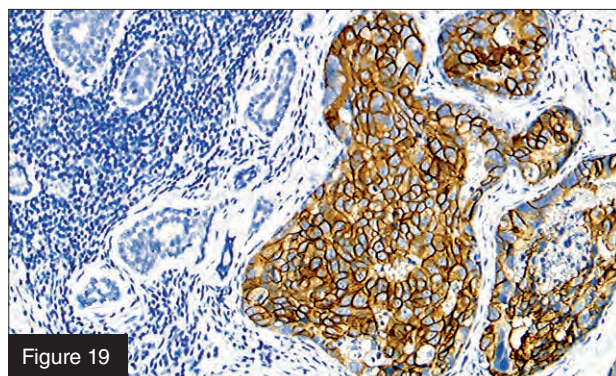
## Staining of Normal Epithelium

Overexpression of HER2 on tumor cells is relative to a baseline level of expression on normal breast epithelium.

- Normal breast tissue rarely overexpresses HER2. Staining of normal ducts may be observed occasionally.
- The sensitivity of HercepTest™ has been established under controlled conditions to stain normal breast epithelium between 0-1+.
- If normal epithelium is staining >1+, the test should be repeated and the protocol should be observed closely.

This phenomenon may be caused by:

- 1 Fixatives other than Neutral Buffered Formalin or Bouin's solution.
- 2 Use of a steamer or microwave rather than a water bath for epitope retrieval.



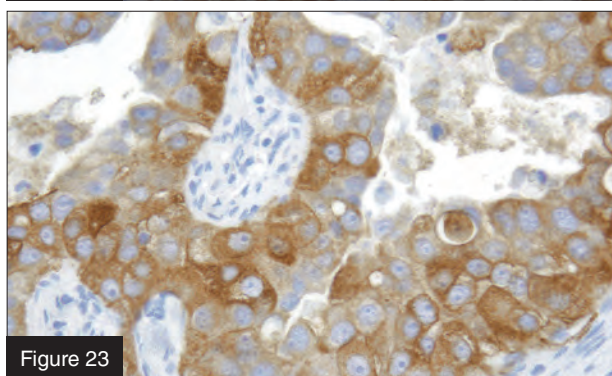
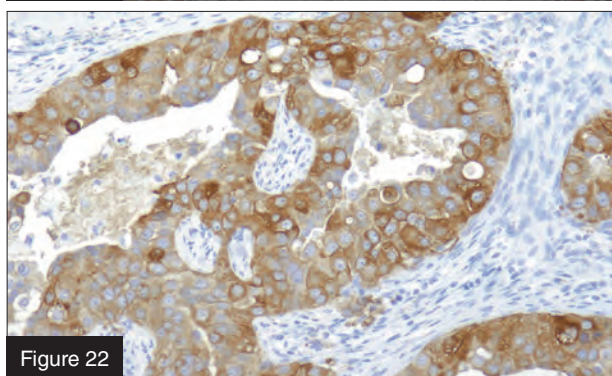
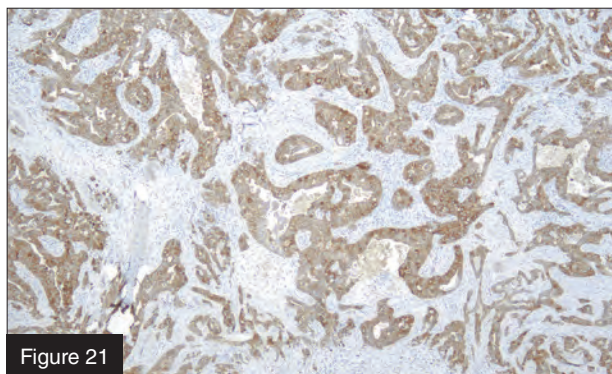
**Figure 19:** Breast carcinoma with no staining of normal ducts on the left and 3+ homogeneous staining on the right. (10x magnification).

**Figure 20:** Breast carcinoma with no staining of normal ducts on the left and 3+ homogeneous staining on the right. (20x magnification).



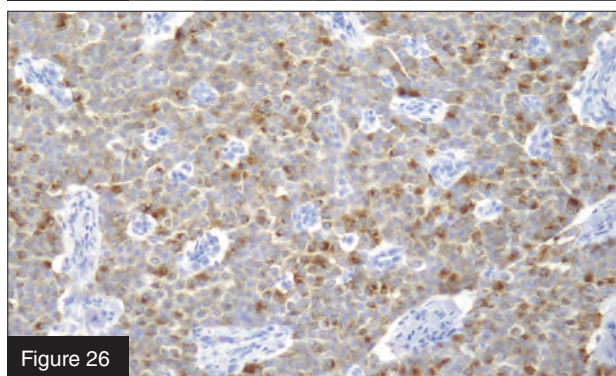
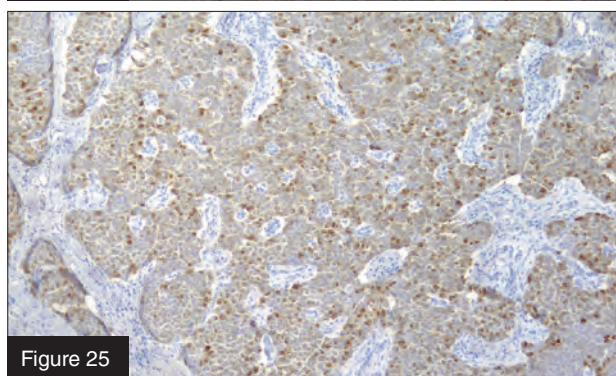
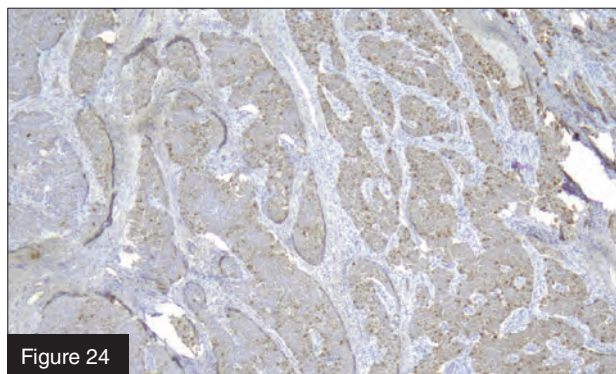
### Cytoplasmic Staining – Homogeneous

Diffuse homogeneous staining is specifically confined to the cytoplasm. Score 0



### Cytoplasmic Staining – “Dot” Artifact

The dot artifact is specific to the cytoplasm. This artifact is associated with tumors having neuroendocrine differentiation. Score 0



**Figure 21:** Breast carcinoma, brown staining is apparent. (4x magnification).

**Figure 22:** In this breast carcinoma, homogeneous non-specific cytoplasmic staining can be seen. (20x magnification).

**Figure 23:** Breast carcinoma with no membranous staining seen. (40x magnification).

**Figure 24:** Breast carcinoma with dot artifact. (4x magnification).

**Figure 25:** Breast carcinoma exhibits brown, dot artifact staining. (10x magnification).

**Figure 26:** Breast carcinoma with brown dots representing cytoplasmic staining, not membrane staining. (20x magnification).



# Artifacts

## Interpreting Artifacts

### Edge Artifact

Commonly, edge artifacts are linked to the preanalytic handling of the tissue. Often the method of surgical extraction is the cause (see Crushing and Thermal artifact sections). This phenomenon is more frequently observed with the advent of stereotactic needle biopsies. This artifact occurs in 3-5% of cases.

- Inadequate processing of thick tissue samples may mimic edge artifact by rendering the central portion of the tissue sub-optimally fixed relative to the peripheral areas. In these circumstances, the immunoreactivity based on the sub-optimal central portion may be mistakenly interpreted as false-negative as optimal fixation is only present at the periphery.
- Frequently, increased staining is observed around the periphery of the tissue specimen, known as the “edge effect”.
  - The edge effect represents artifact due to tissue drying prior to fixation.
  - If the positive reaction is only at the edge of the tissue section (i.e. a few layers of staining at the periphery and ending abruptly with penetration into the centrally located tumor), grading at the edge of the tissue specimen should be avoided.

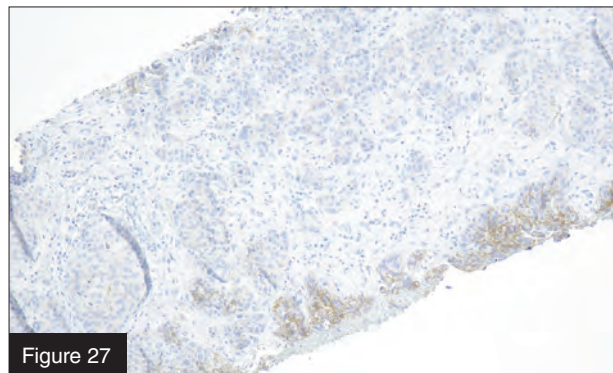


Figure 27

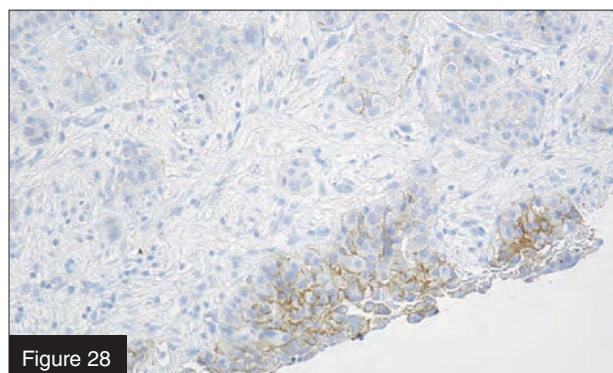


Figure 28

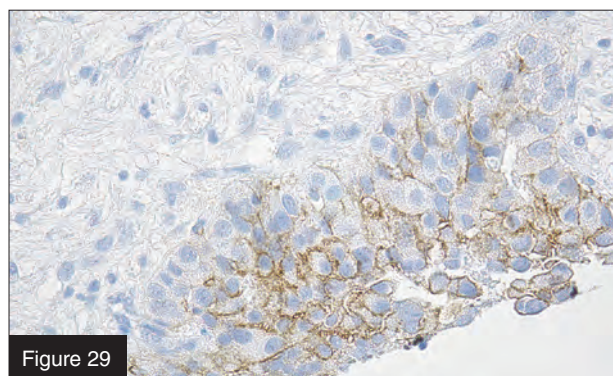


Figure 29

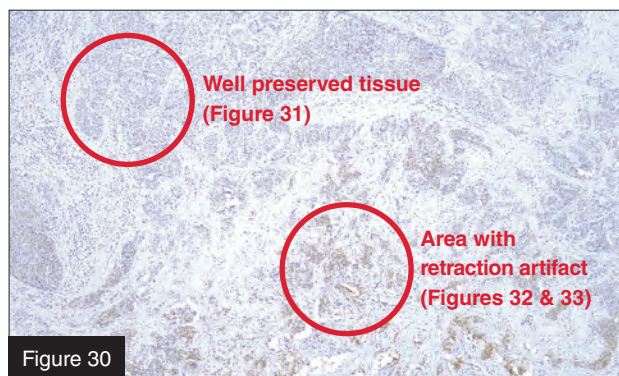
**Figure 27:** Breast carcinoma, edge artifact, is obvious. (10x magnification).

**Figure 28:** Breast carcinoma, edge artifact. (20x magnification).

**Figure 29:** Breast carcinoma, edge artifact. (40x magnification).

### Retraction Artifact

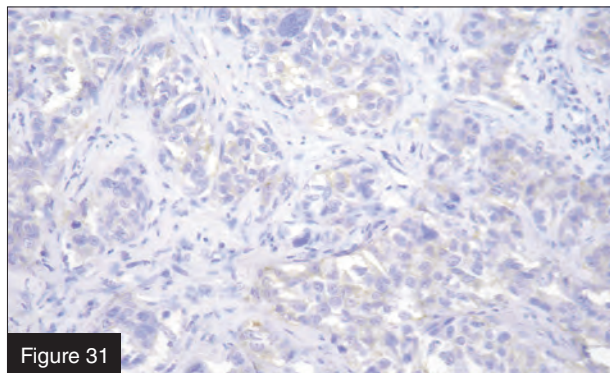
Retraction artifact is edge artifact on a cellular level and can be observed in diagnostic entities such as basal cell carcinoma. Unfortunately, in many infiltrating breast carcinomas, the desmoplastic status may cause retraction of the epithelial cells from the stroma. This creates small spaces where antibody and chromogen can pool around the epithelial cells forming circumferential deposition of the brown stain. This artifact requires thorough examination of the intercellular areas (i.e. cell-to-cell interfaces not the cell-to-stroma interface). Retraction artifacts occur in 2-5% of cases.



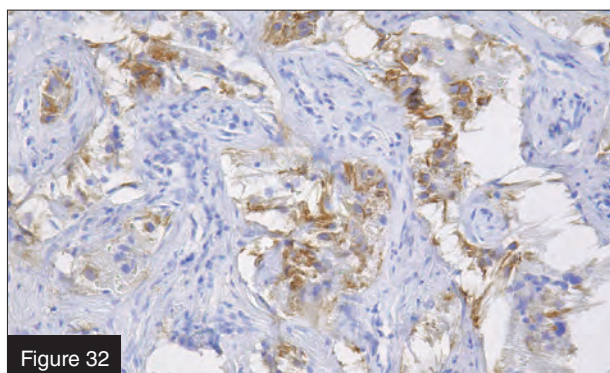
Retraction of the epithelial cells from the stroma with deposition of the chromogen circumferentially around clusters of cells but little to no immunoreactivity in the cell-to-cell interface. Score 1+

**Figure 30:**

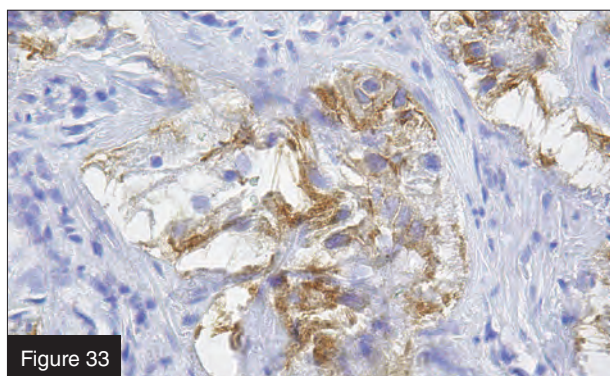
Breast carcinoma. (4x magnification).



**Figure 31**



**Figure 32**



**Figure 33**

**Figure 31:** Immunoreactivity in the well-preserved area of breast carcinoma is 1+. (10x magnification).

**Figure 32:** Breast carcinoma with non-specific immunoreactivity is apparent as retraction artifact. (20x magnification).

**Figure 33:** Breast carcinoma with non-specific immunoreactivity is confirmed. (40x magnification).



### Thermal Artifact

This artifact occurs at the preanalytic stage. The surgical removal of tissue with an electrocautery instrument is detrimental to the preservation of the tissue. This is especially true and inversely proportional to the size of the tissue (i.e. the smaller the biopsy the more damage incurred). The frequency is dependent upon the surgeon and his/her preferred method of tissue procurement. Thermal artifacts may occur in 3-5% of cases.

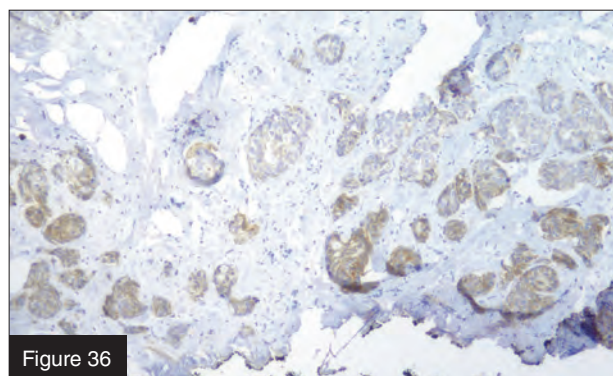
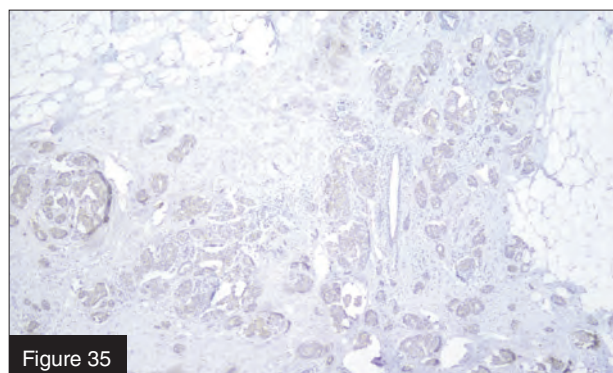
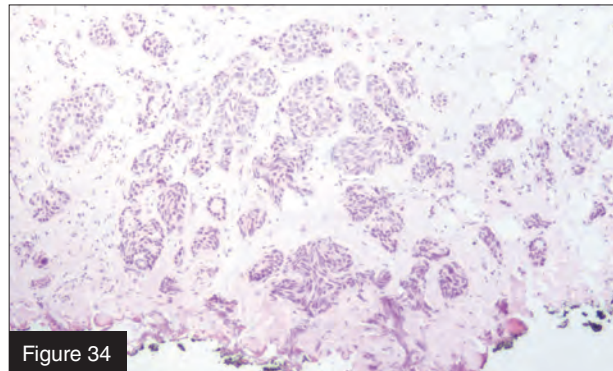
---

#### Example of Thermal Artifact

**Figure 34:** Breast carcinoma with thermal artifact can best be seen on the H&E. The majority of the injury can be seen at the edge. As heat transfers through the tissue, less and less can be seen. (10x magnification).

**Figure 35:** Breast carcinoma with burning around the edges is slightly apparent. Central part of the lesion is the best preserved area. 1+ score is apparent. (4x magnification).

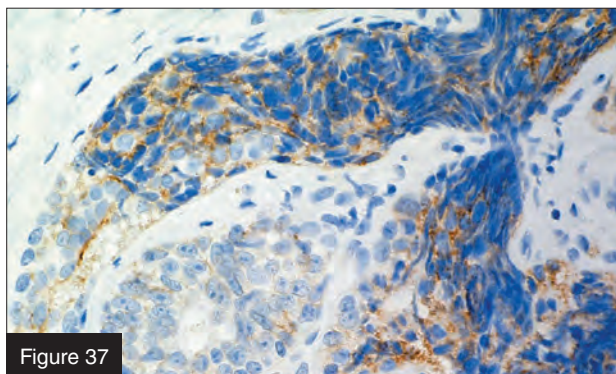
**Figure 36:** Breast carcinoma with thermal artifact. Score: 1+ Non-specific deposition of the chromogen in a pattern consistent with specific HER2 is localized in areas with typical morphologic features of the thermal injury. The centrally located tumor is HER2 negative. (10x magnification).



### Crush Artifact

Crush artifact is related closely to edge artifact. This artifact may be encountered more often in stereotactic needle biopsies. It is presumed that the tissue injury occurs during the extraction of the tissue from the needle rather than from the actual biopsy process. Regardless, the compression of the tissues along the edges of the core can produce a linear staining that has to be interpreted as artifact. This artifact occurs in less than 1% of cases.

- Inadvertent crushing of the tissue occasionally occurs during sectioning resulting in morphologically distorted cellular architecture.
- When compared to surrounding cells, stronger staining may be observed in crushed cells. Crushed cells typically demonstrate condensed nuclei. **Crushed cells should be avoided in grading.**



- Deposition of the chromogen is characteristic in areas where the cells are crushed while the central well-preserved cells are devoid of immunoreactivity.

### Decalcification Artifact

The spinal vertebrae and other areas of the human skeleton are sites of metastatic carcinoma. Interventional radiology has facilitated access to domains of the body and has provided another source of specimens that can be tested for analytes such as HER2. However, in order to render the tissue soft enough to cut on a histologist's microtome (at 4-5 microns) the tissue has to be decalcified. This traditionally is accomplished by exposing the bony tissue to a variety of available decalcification solutions. This renders the tissue soft enough to obtain good histologic section but also renders the tissue less than optimal for immunostains. **The use of HercepTest™ on decalcified tissues has not been validated and is not recommended.**

---

**Carcinoma has darker staining on crushed areas.  
Score 1+**

**Figure 37:** Breast carcinoma showing crush artifact. (40x magnification).



# Effects of Fixation

Standardization of fixation is very important when using HercepTest™. These stains have been fixed for 18-24 hours and for one week, respectively.

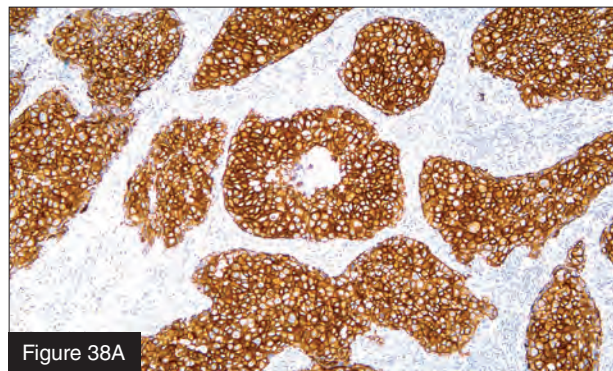


Figure 38A

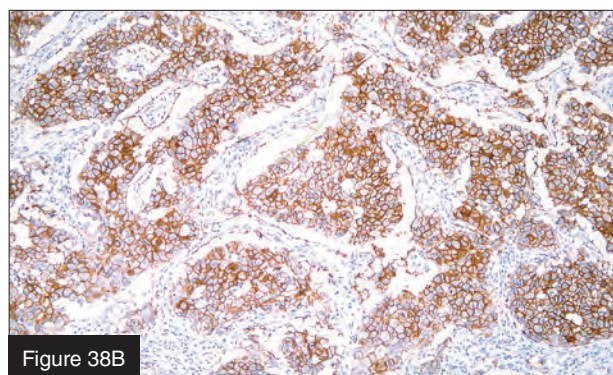


Figure 38B

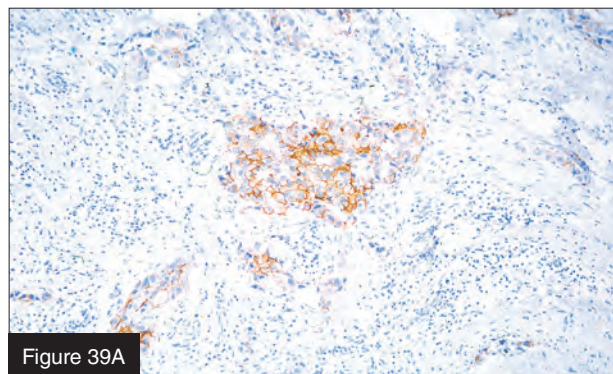


Figure 39A

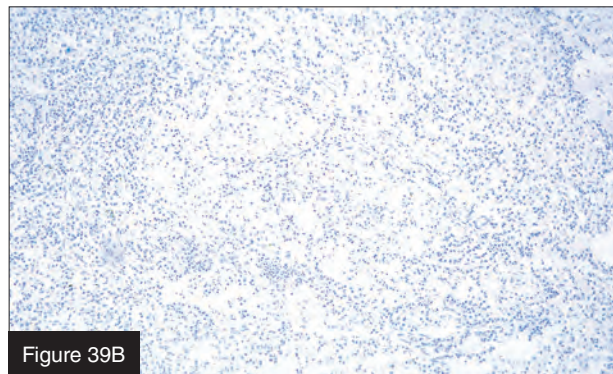


Figure 39B

---

**Figure 38A:** Breast carcinoma shows a strong 3+ staining with the appropriate fixation time.

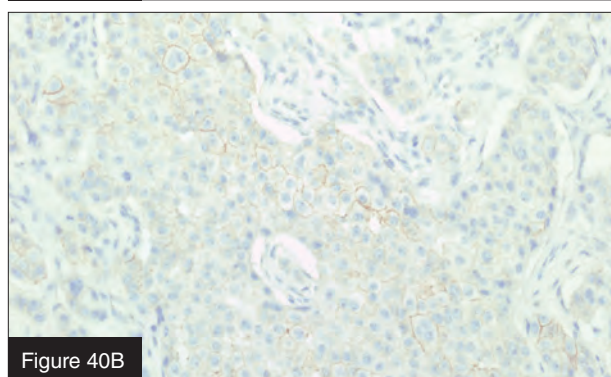
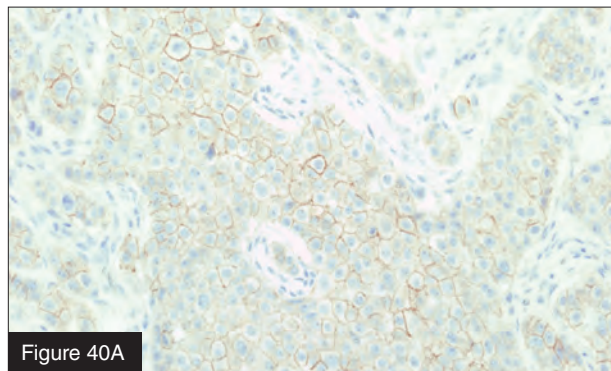
**Figure 38B:** Breast carcinoma shows a noticeably weaker staining, but still 3+ after the extended fixation.

**Figure 39A:** Breast carcinoma shows 2+ staining with the appropriate fixation time.

**Figure 39B:** Breast carcinoma shows negative staining after the extended fixation.

# Effects of Insufficient Target Retrieval

It is important to adhere to the target retrieval procedure described in the Instructions for Use for HercepTest™. The stains displayed to the left are sections from the same tissue, but exposed to appropriate epitope retrieval and insufficient epitope retrieval, respectively.



**Figure 40A:** Breast carcinoma displaying a 2+ staining when appropriate epitope retrieval is used (40 min at 95-99 °C).  
(20x magnification).

**Figure 40B :**Breast carcinoma displaying a 1+ staining when insufficient epitope retrieval is used (20 min at 90 °C).  
(20x magnification).



# Effects of Excessive Tissue Drying

## Loss of Specific Staining

Excessive heating for more than 1 hour at  $\geq 60^{\circ}\text{C}$  may cause a significant decrease or loss of the specific membrane-associated HER2 immunoreactivity.

The decreased HER2 immunostaining is likely caused by the destruction of the epitope(s) recognized by the HER2 antibodies.

- Use proper procedure for tissue drying: The drying temperature should be  $60^{\circ}\text{C}$  for a maximum of 1 hour,  $37^{\circ}\text{C}$  overnight, or room temperature for 12 hours or longer.
- Use validated equipment (oven, thermometer) when conducting the tissue drying.

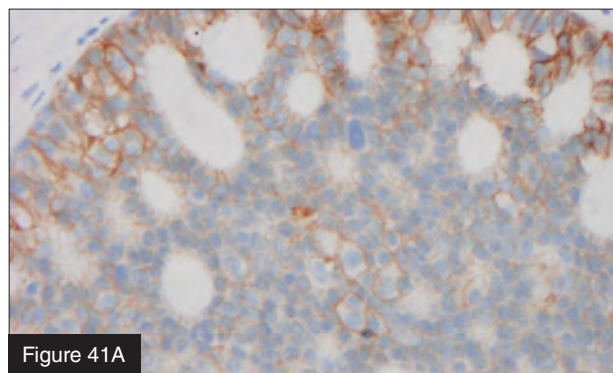


Figure 41A

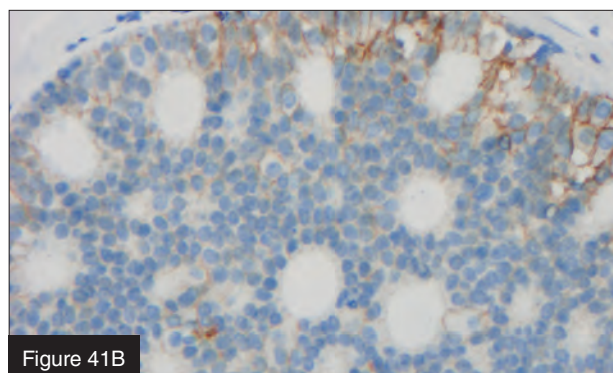


Figure 41B

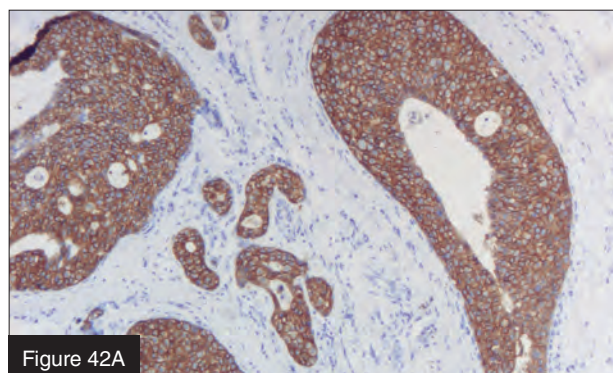


Figure 42A

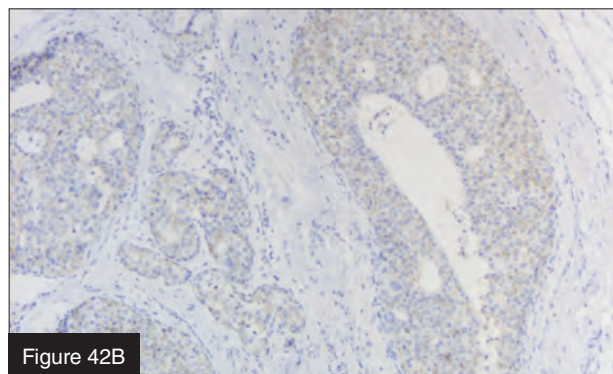


Figure 42B

---

**Figure 41A:** Breast carcinoma displaying a 2+ staining after appropriate tissue drying.

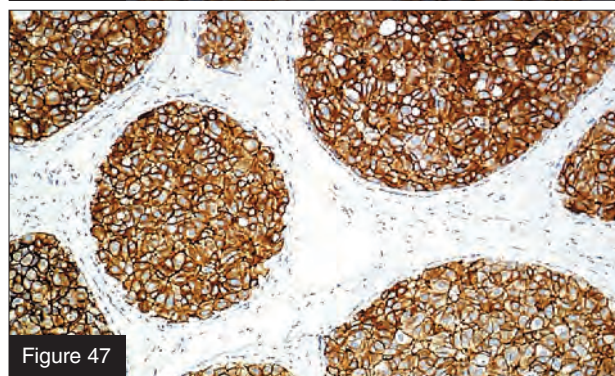
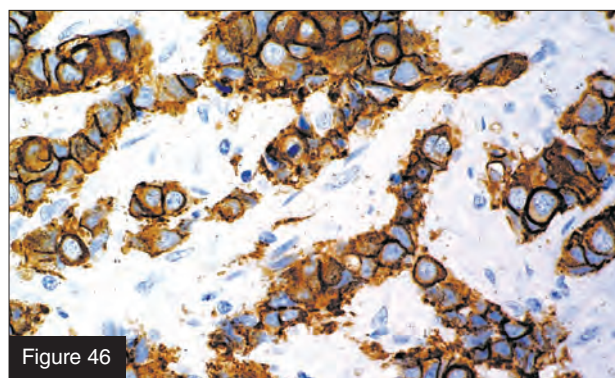
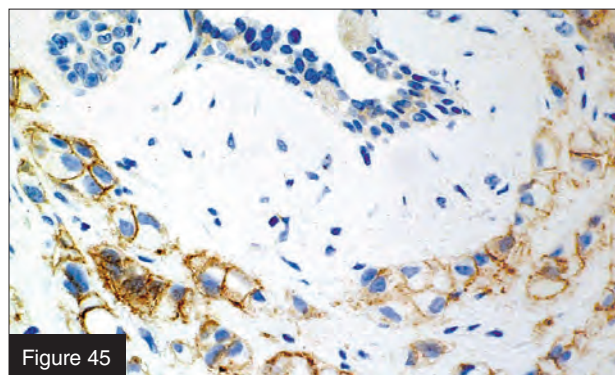
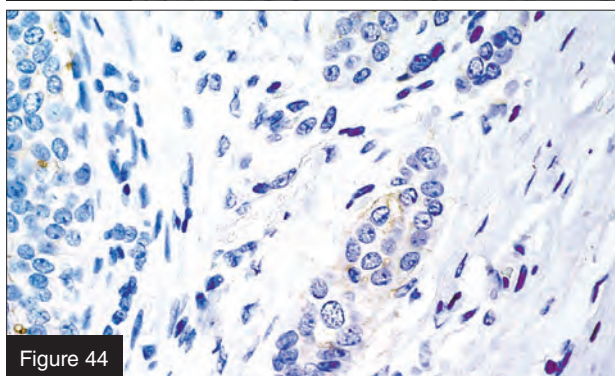
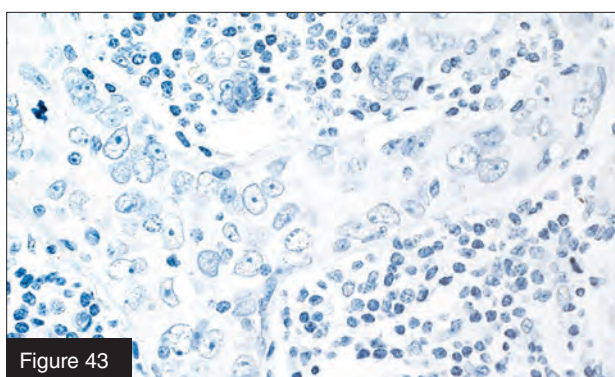
**Figure 41B:** Breast carcinoma displaying a noticeably weaker 1+ staining after excessive tissue drying.

**Figure 42A:** Breast carcinoma displaying a strong 3+ staining after appropriate tissue drying.

**Figure 42B:** Breast carcinoma displaying a negative staining after excessive tissue drying.

# Staining Images

## HER2 Expression in Various Diagnostic Entities



**Figure 43:** Example of poorly differentiated ductal carcinoma. Score 0 (40x magnification).

**Figure 44:** Example of well differentiated ductal carcinoma. Score 1+ (40x magnification).

**Figure 45:** Example of moderately differentiated ductal carcinoma. Score 2+ (40x magnification).

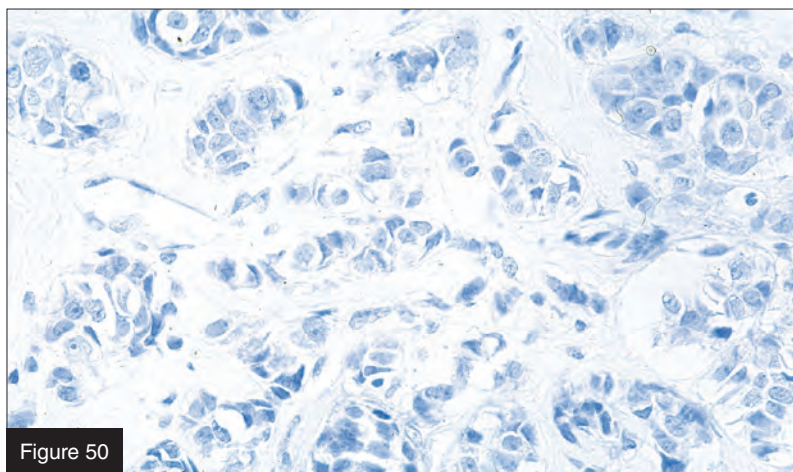
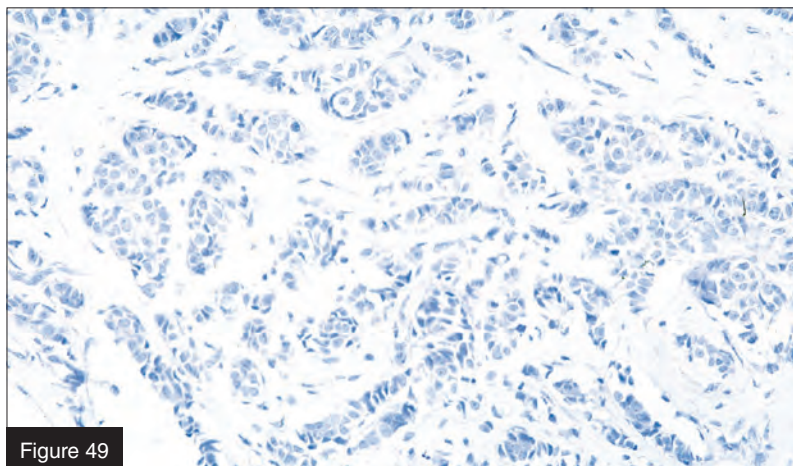
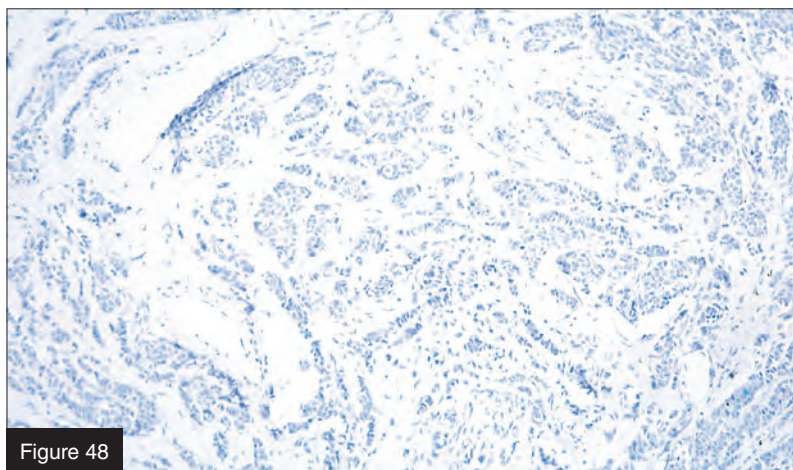
**Figure 46:** Example of poorly differentiated ductal carcinoma. Score 3+ (40x magnification).

**Figure 47:** Example of intraductal carcinoma (DCIS). Score 0 (40x magnification).



## HercepTest™ Score 0

No staining is seen in this invasive ductal carcinoma.



---

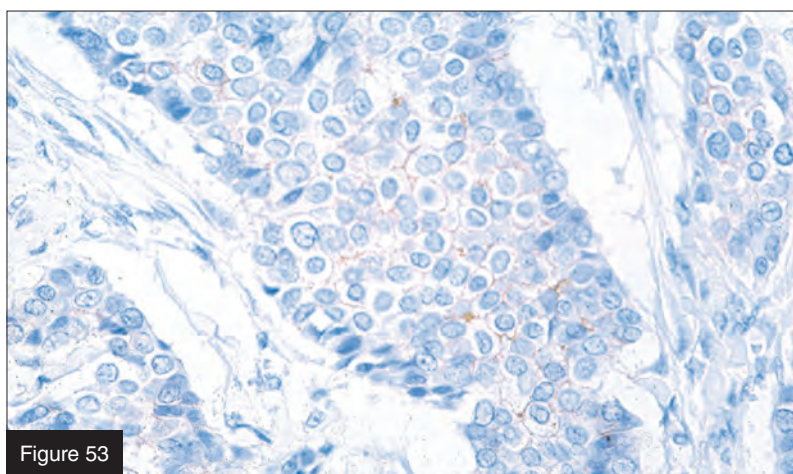
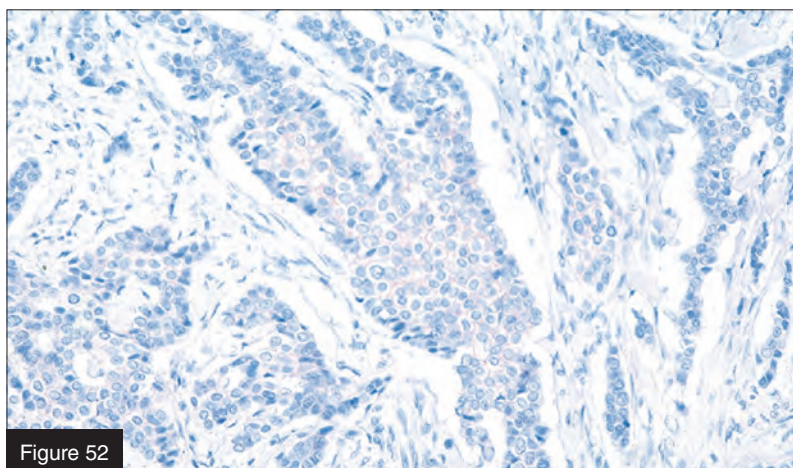
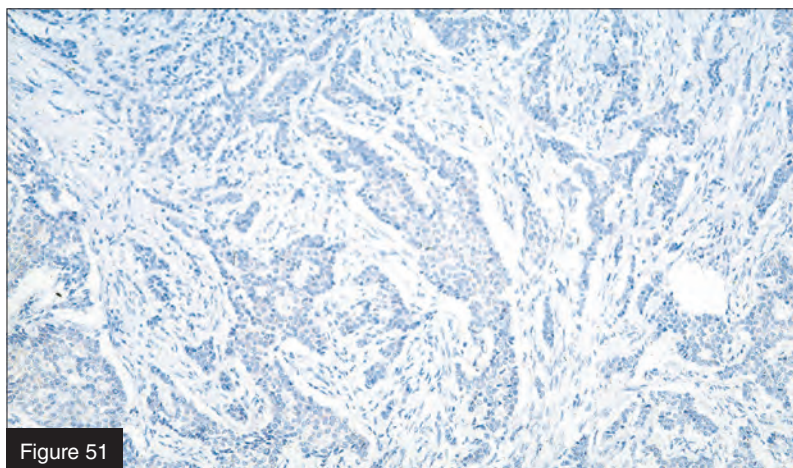
**Figure 48:** Breast carcinoma. Score 0  
(4x magnification).

**Figure 49:** Breast carcinoma. Score 0  
(10x magnification).

**Figure 50:** Breast carcinoma. Score 0  
(20x magnification).

## HercepTest™ Score 1+

The infiltrating tumor cells are weakly stained and do not demonstrate complete membrane staining.



---

**Figure 51:** Breast carcinoma. Score 1+ (4x magnification).

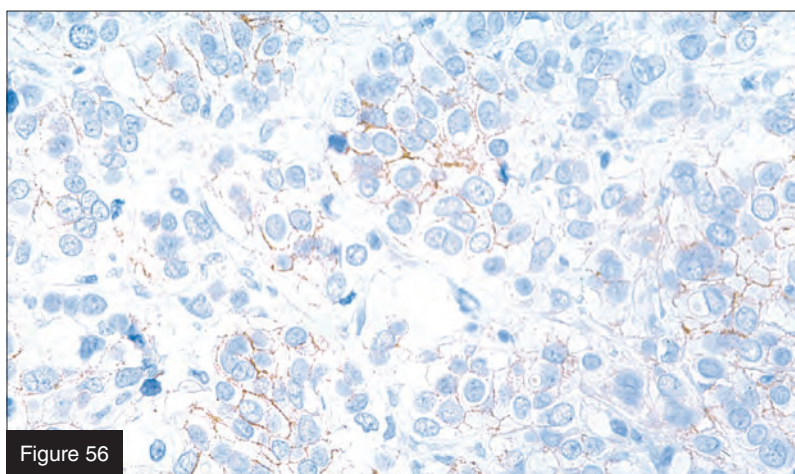
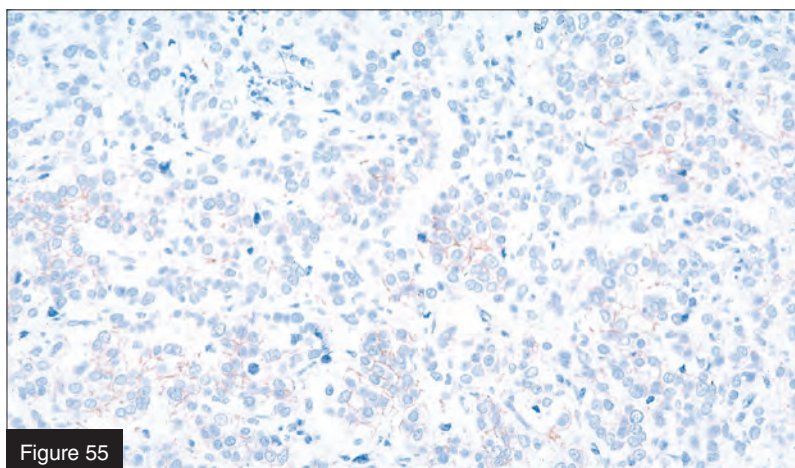
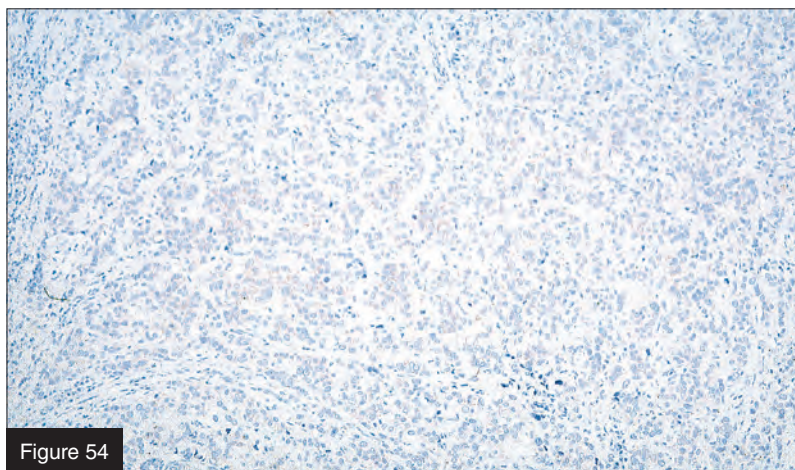
**Figure 52:** Breast carcinoma. Score 1+ (10x magnification).

**Figure 53:** Breast carcinoma. Score 1+ (20x magnification).



## HercepTest™ Score 1+

The infiltrating tumor cells are weakly stained and do not demonstrate complete membrane staining.



---

**Figure 54:** Breast carcinoma. Score 1+ (4x magnification).

**Figure 55:** Breast carcinoma. Score 1+ (10x magnification).

**Figure 56:** Breast carcinoma. Score 1+ (20x magnification).



## HercepTest™ Score 1+

The infiltrating tumor cells are weakly stained and do not demonstrate complete membrane staining.

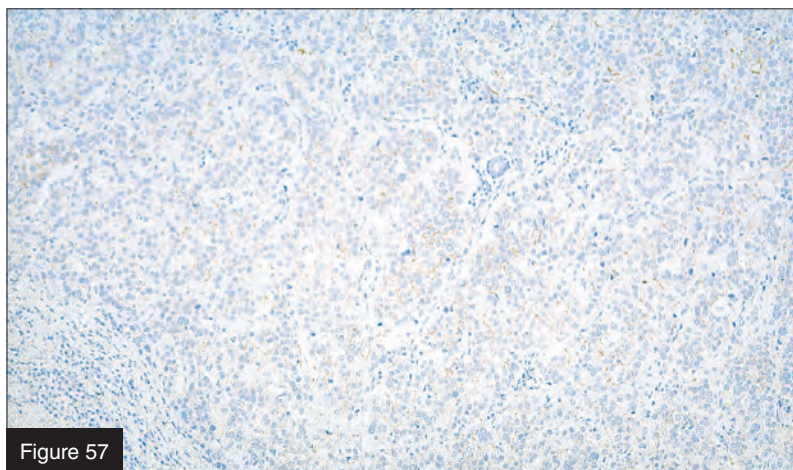


Figure 57

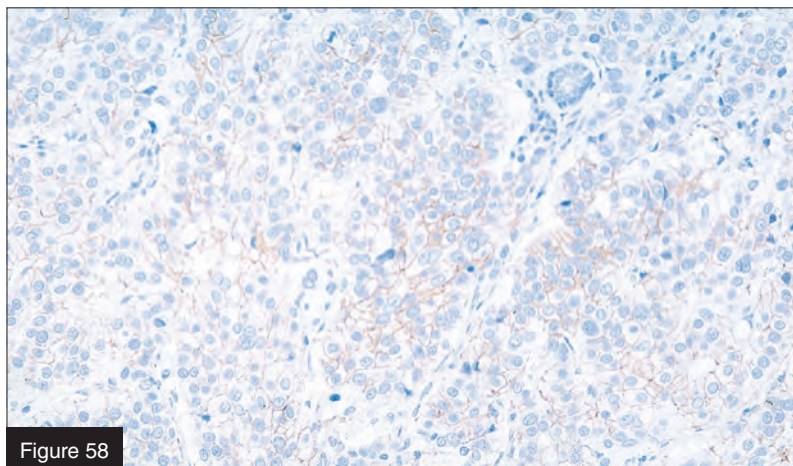


Figure 58

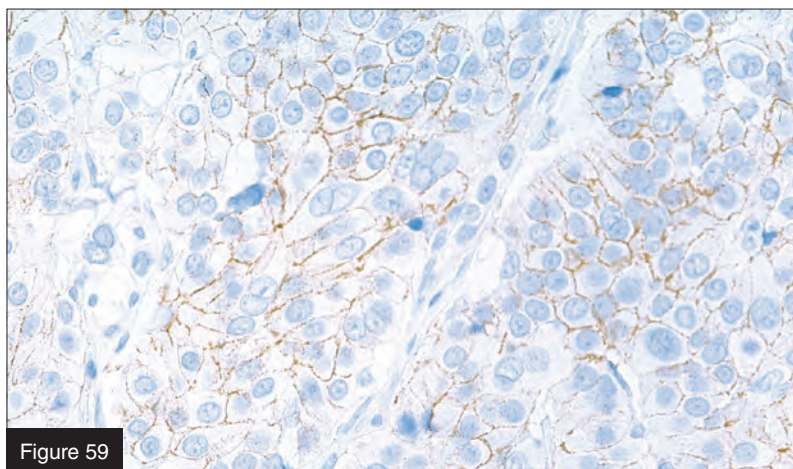


Figure 59

---

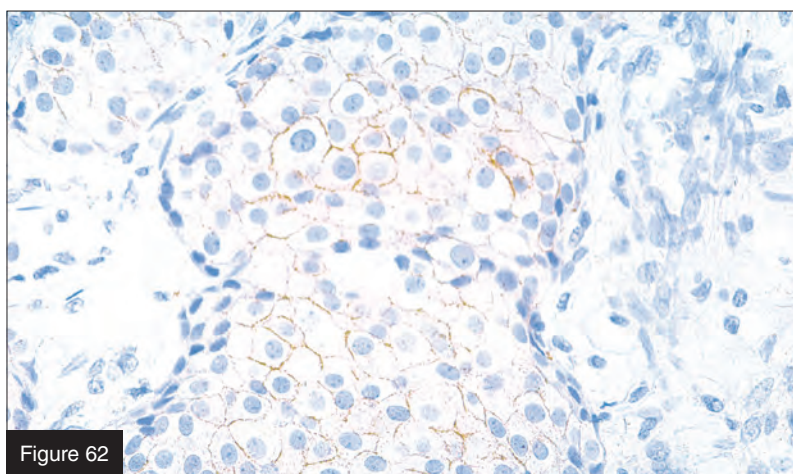
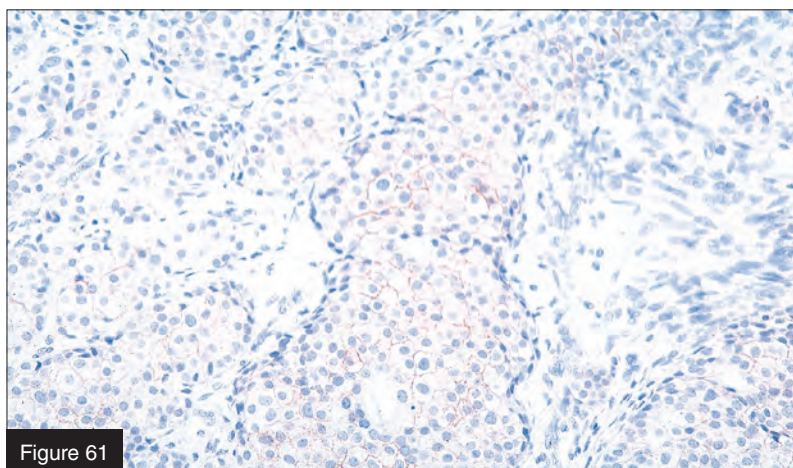
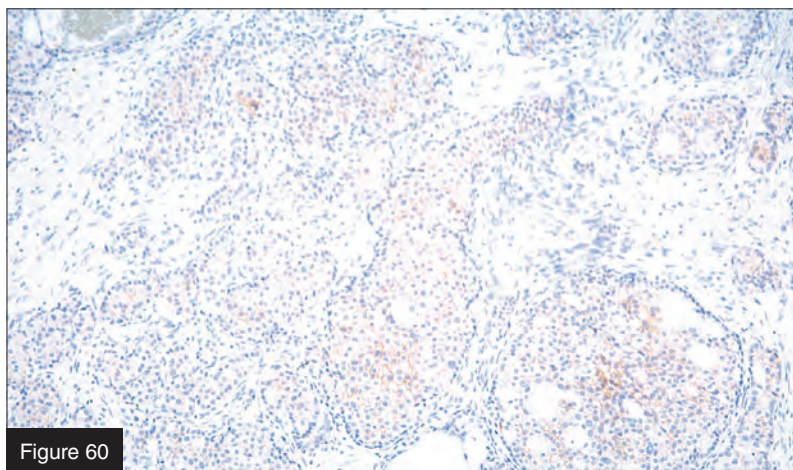
**Figure 57:** Breast carcinoma. Score 1+ (4x magnification).

**Figure 58:** Breast carcinoma. Score 1+ (10x magnification).

**Figure 59:** Breast carcinoma. Score 1+ (20x magnification).

## HercepTest™ Score 1+

The infiltrating tumor cells are weakly stained and do not demonstrate complete membrane staining.



**Figure 60:** Breast carcinoma. Score 1+ (4x magnification).

**Figure 61:** Breast carcinoma. Score 1+ (10x magnification).

**Figure 62:** Breast carcinoma. Score 1+ (20x magnification).



## HercepTest™ Score 2+

These infiltrating tumor cells exhibit complete membrane staining; the intensity is moderate.

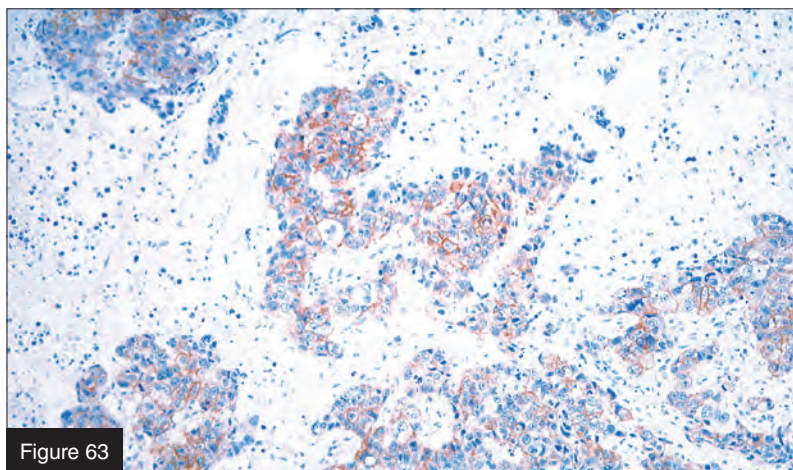


Figure 63

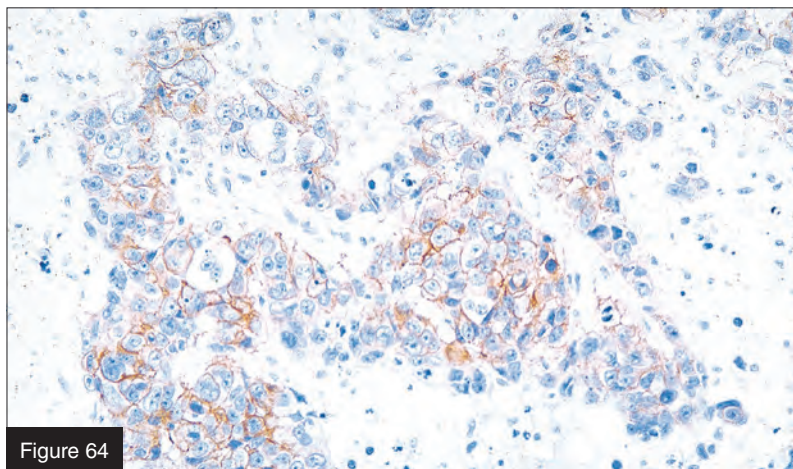


Figure 64

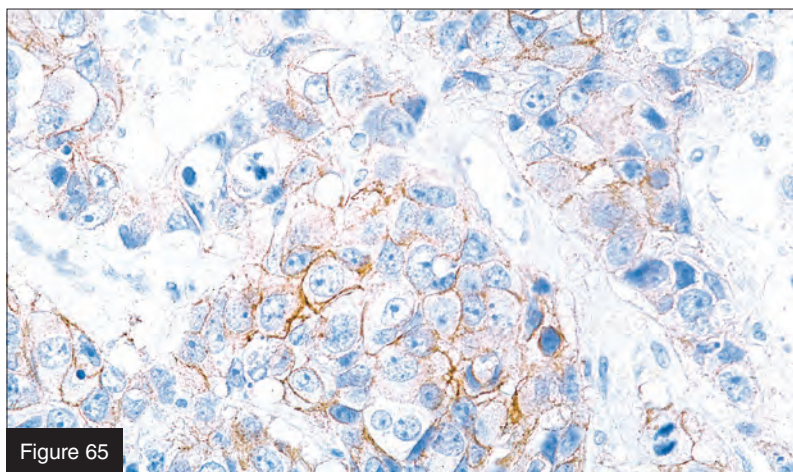


Figure 65

---

**Figure 63:** Breast carcinoma. Score 2+  
(4x magnification).

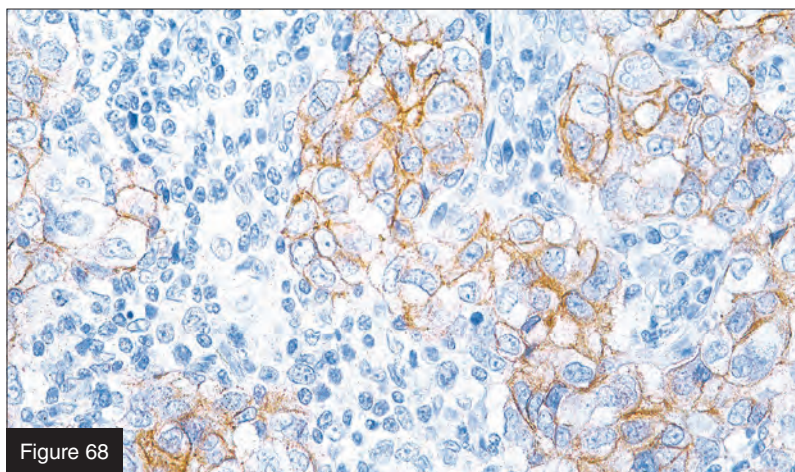
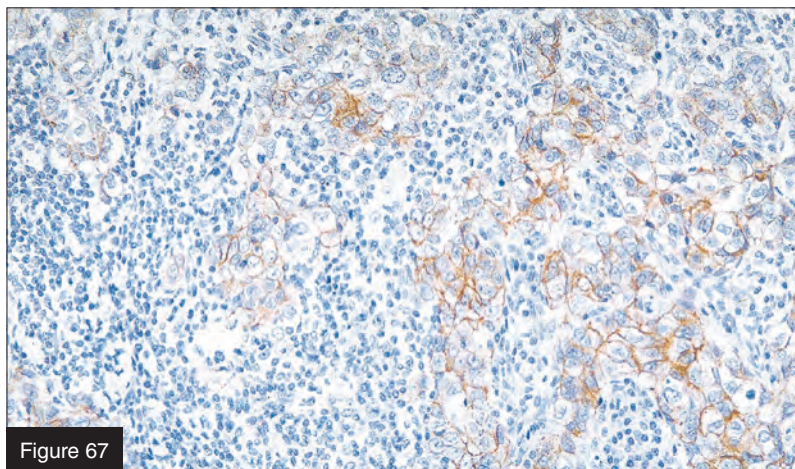
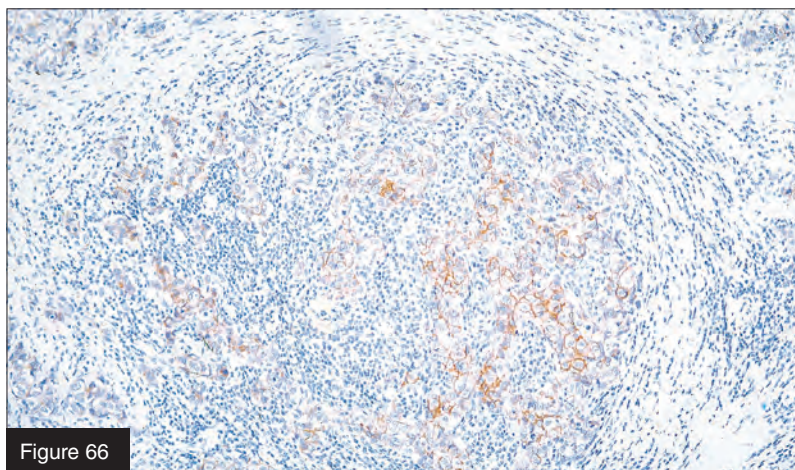
**Figure 64:** Breast carcinoma. Score 2+  
(10x magnification).

**Figure 65:** Breast carcinoma. Score 2+  
(20x magnification).



## HercepTest™ Score 2+

These infiltrating tumor cells exhibit complete membrane staining; the intensity is moderate.



**Figure 66:** Breast carcinoma. Score 2+ (4x magnification).

**Figure 67:** Breast carcinoma. Score 2+ (10x magnification).

**Figure 68:** Breast carcinoma. Score 2+ (20x magnification).

## HercepTest™ Score 2+

These infiltrating tumor cells exhibit complete membrane staining; the intensity is moderate.

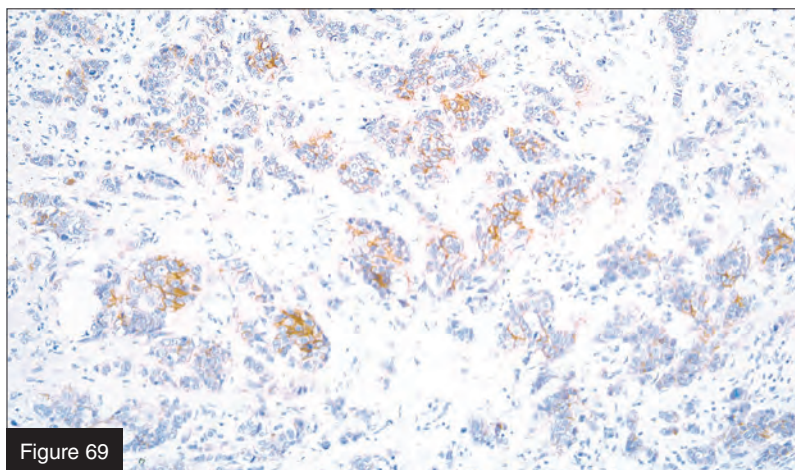


Figure 69

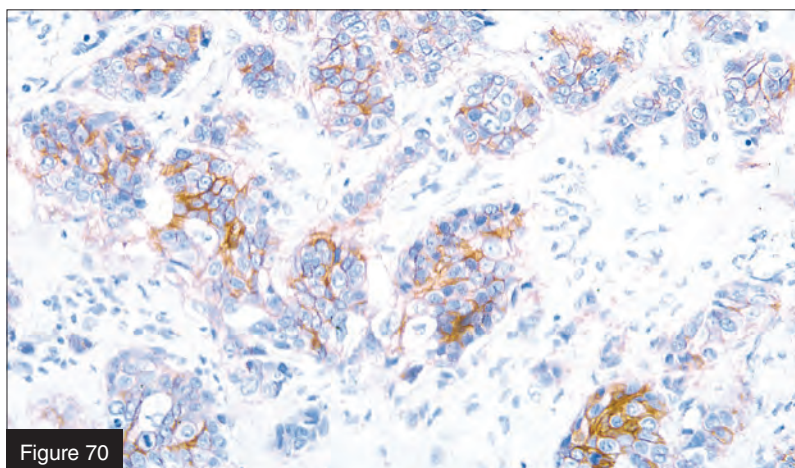


Figure 70

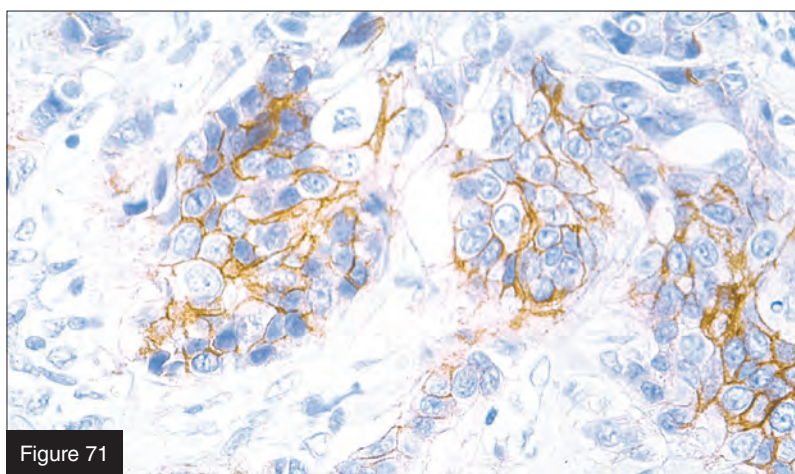


Figure 71

---

**Figure 69:** Breast carcinoma. Score 2+ (4x magnification).

**Figure 70:** Breast carcinoma. Score 2+ (10x magnification).

**Figure 71:** Breast carcinoma. Score 2+ (20x magnification).



## HercepTest™ Score 2+

These infiltrating tumor cells exhibit complete membrane staining; the intensity is moderate.

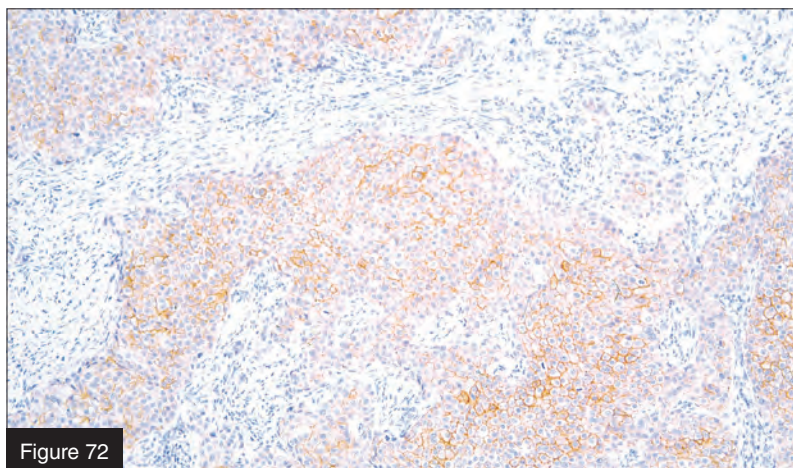


Figure 72

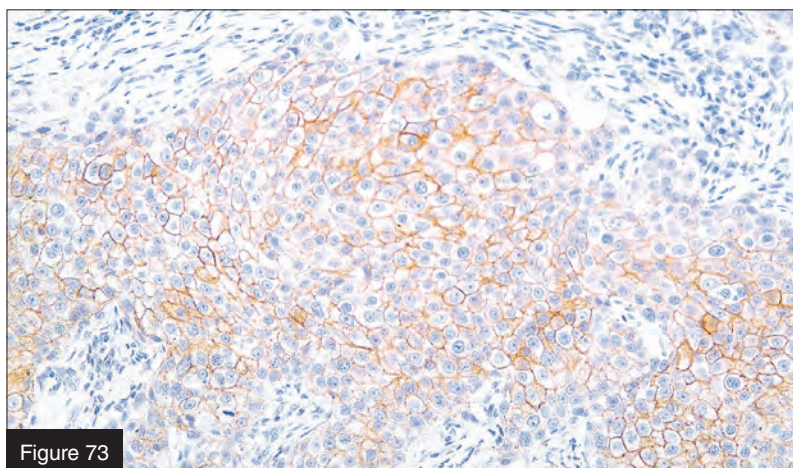


Figure 73

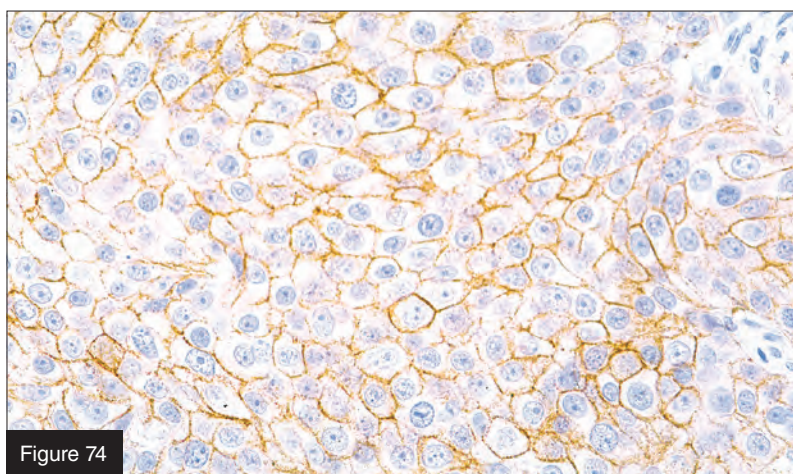


Figure 74

---

**Figure 72:** Breast carcinoma. Score 2+ (4x magnification).

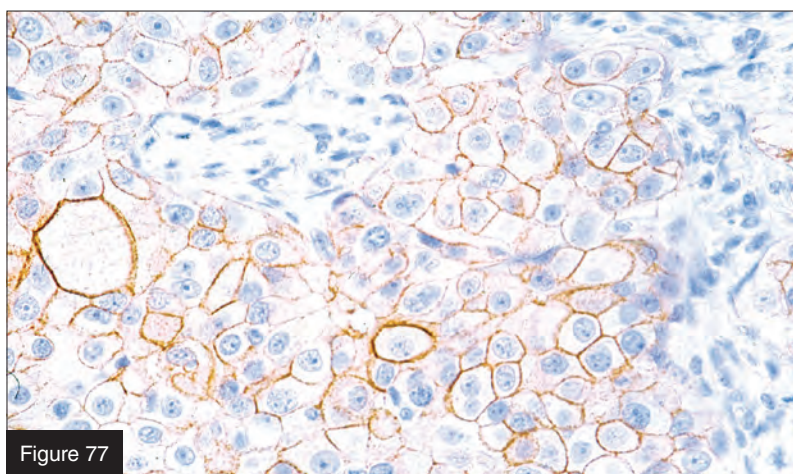
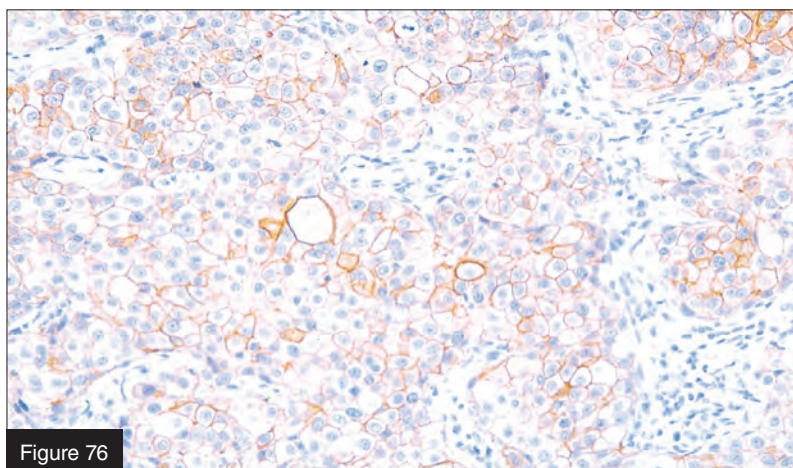
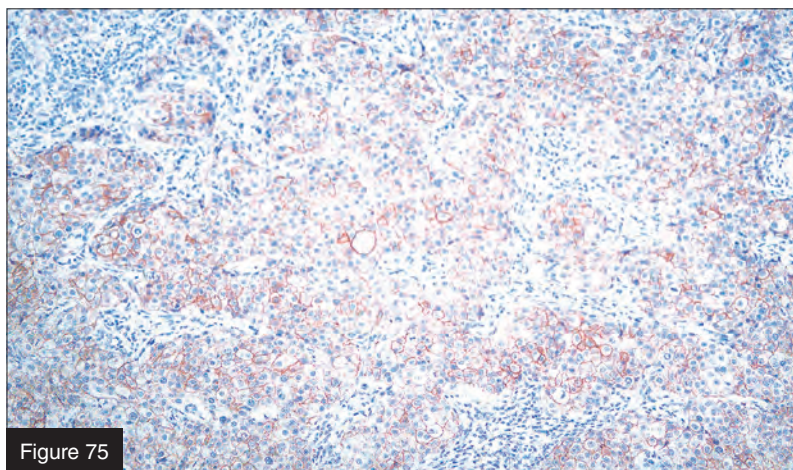
**Figure 73:** Breast carcinoma. Score 2+ (10x magnification).

**Figure 74:** Breast carcinoma. Score 2+ (20x magnification).



## HercepTest™ Score 2+

These infiltrating tumor cells exhibit complete membrane staining; the intensity is moderate.



---

**Figure 75:** Breast carcinoma. Score 2+ (4x magnification).

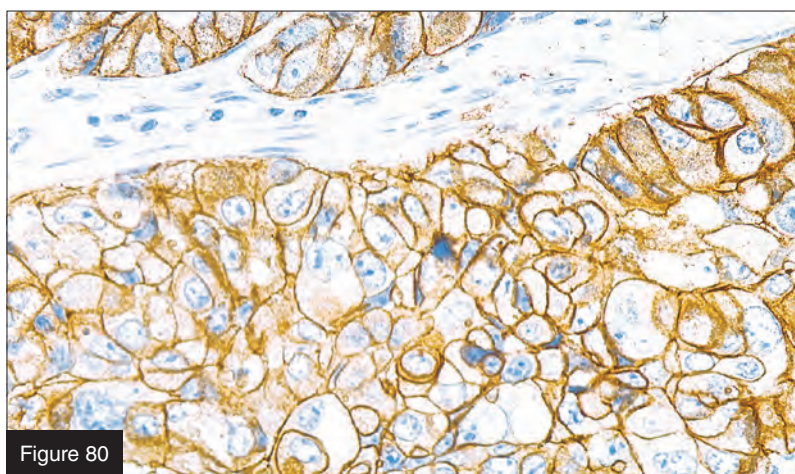
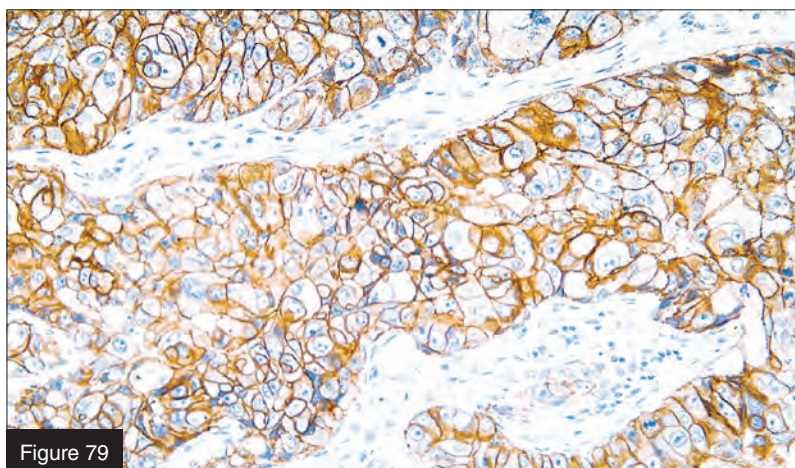
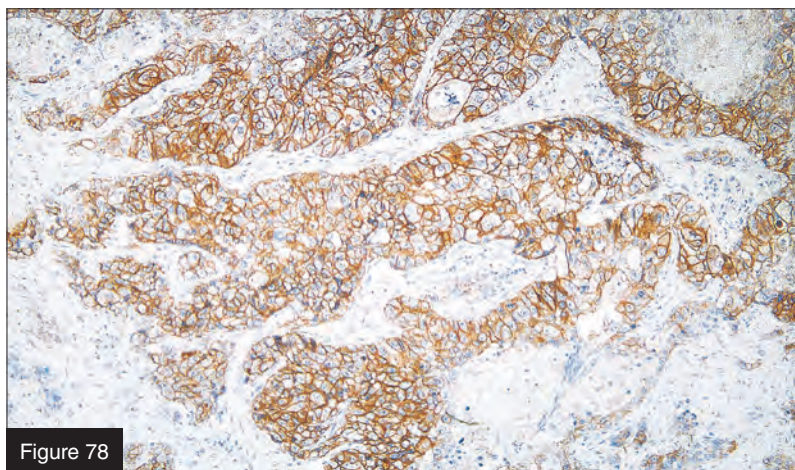
**Figure 76:** Breast carcinoma. Score 2+ (10x magnification).

**Figure 77:** Breast carcinoma. Score 2+ (20x magnification).



## HercepTest™ Score 3+

The majority of infiltrating tumor cells exhibit intense, complete membrane staining.



**Figure 78:** Breast carcinoma. Score 3+ (4x magnification).

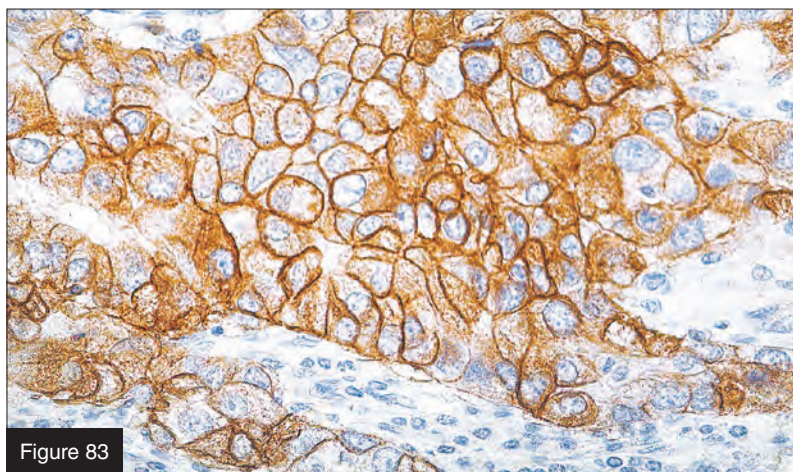
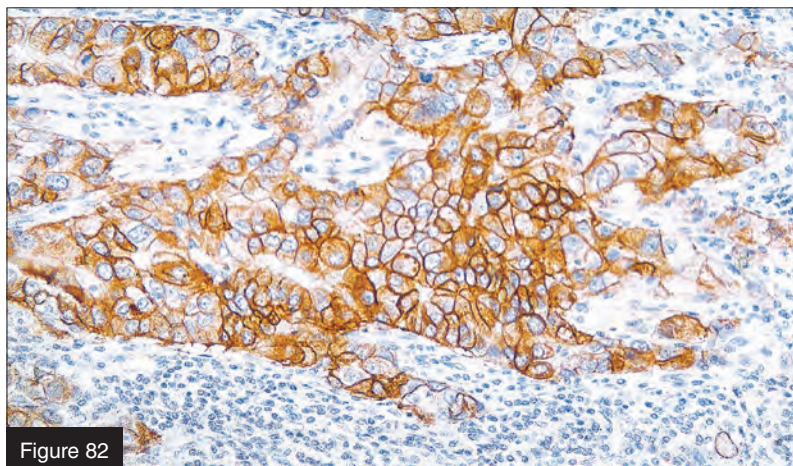
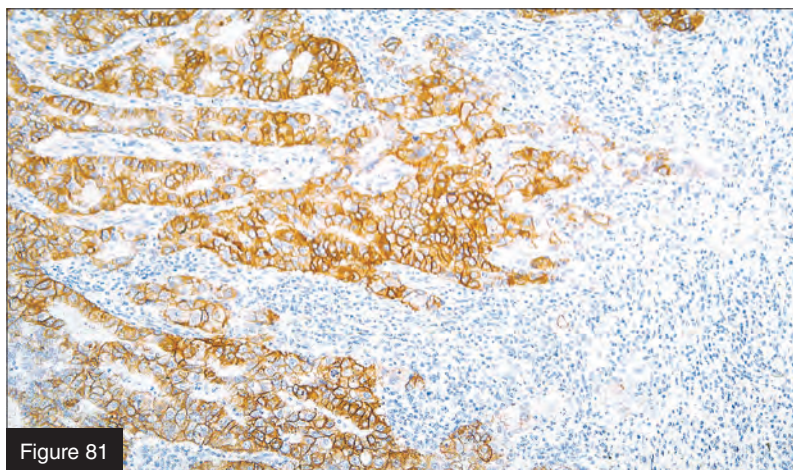
**Figure 79:** Breast carcinoma. Score 3+ (10x magnification).

**Figure 80:** Breast carcinoma. Score 3+ (20x magnification).



## HercepTest™ Score 3+

The majority of infiltrating tumor cells exhibit intense, complete membrane staining.



**Figure 81:** Breast carcinoma. Score 3+ (4x magnification).

**Figure 82:** Breast carcinoma. Score 3+ (10x magnification).

**Figure 83:** Breast carcinoma. Score 3+ (20x magnification).



## HercepTest™ Score 3+

The majority of infiltrating tumor cells exhibit intense, complete membrane staining.

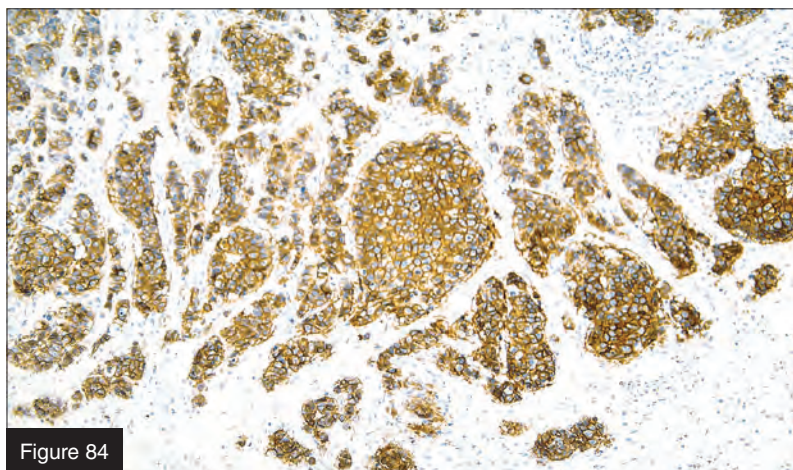


Figure 84

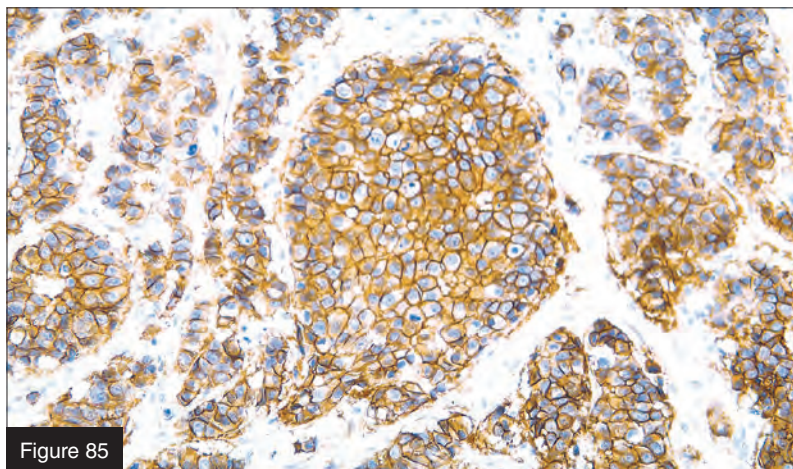


Figure 85

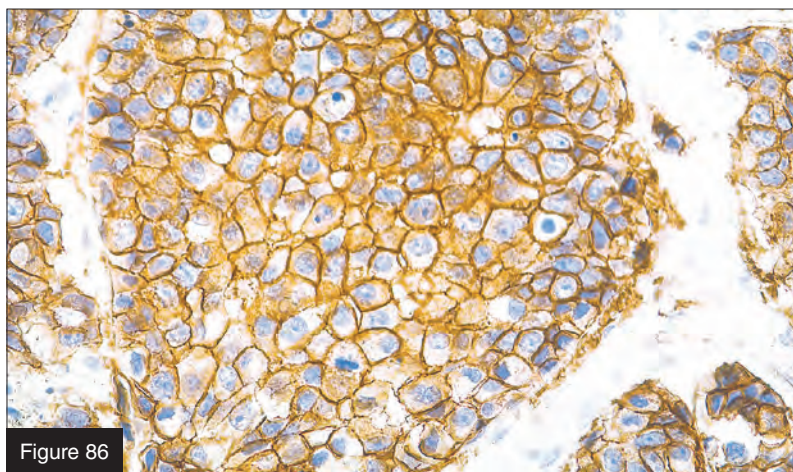


Figure 86

---

**Figure 84:** Breast carcinoma. Score 3+  
(4x magnification).

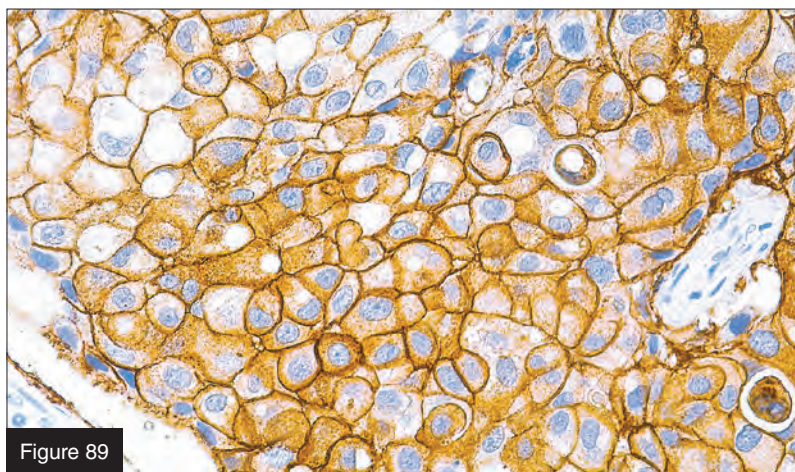
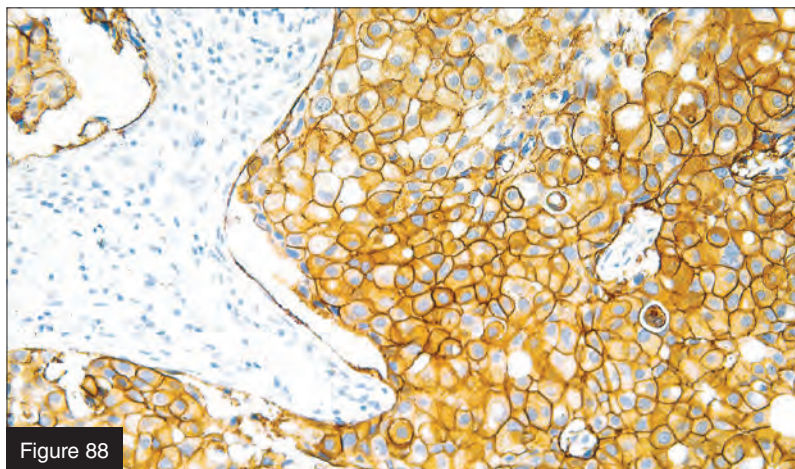
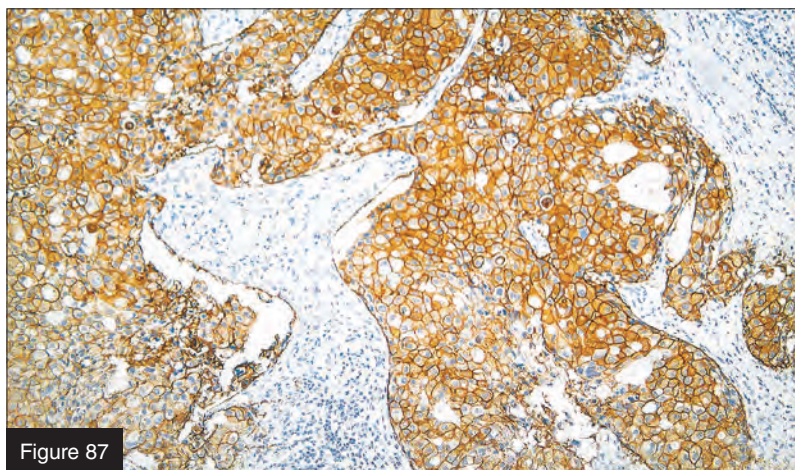
**Figure 85:** Breast carcinoma. Score 3+  
(10x magnification).

**Figure 86:** Breast carcinoma. Score 3+  
(20x magnification).



## HercepTest™ Score 3+

The majority of infiltrating tumor cells exhibit intense, complete membrane staining.



---

**Figure 87:** Breast carcinoma. Score 3+  
(4x magnification).

**Figure 88:** Breast carcinoma. Score 3+  
(10x magnification).

**Figure 89:** Breast carcinoma. Score 3+  
(20x magnification).



# Troubleshooting Guide

## Troubleshooting Guideline for HercepTest™

Problem	Probable Cause	Suggested Action	Reference
1. No staining of slides	1a. Programming error. Reagents not used in proper order.	Check programming grid to verify that the staining run was programmed correctly.	
	1b. Reagent vials were not loaded in the correct locations in the reagent racks.	Check the Reagent Map to verify the proper location of reagent vials.	
	1c. Insufficient reagent on tissue section.	Ensure that enough reagent is loaded into the reagent vials prior to commencing the run. Refer to the Reagent Map for volumes required. Ensure that spreading of reagent is optimal.	HercepTest™ Interpretation Manual Artificial Heterogeneous Staining (page 20)
	1d. Sodium azide in Wash Solution.	Use fresh preparation of Wash Buffer provided in the kit.	
	1e. Excessive heating for more than one hour at $\geq 60^{\circ}\text{C}$ may cause a significant decrease or loss of the specific membrane-associated HER2 immunoreactivity.	Air dry the tissue sections at room temperature for a minimum of 12 hours or until dry. Alternatively, dry at $37^{\circ}\text{C}$ overnight or dry at $60^{\circ}\text{C}$ for a maximum of one hour. Drying of tissue sections at elevated temperatures must only be performed in a calibrated oven with uniform heat distribution.	HercepTest™ Interpretation Manual Excessive Tissue Drying. Loss of specific staining (page 30)
2. Weak staining of slides	2a. Inadequate epitope retrieval.	Verify that Epitope Retrieval Solution reaches $95\text{--}99^{\circ}\text{C}$ for full 40 minutes and is allowed to cool for an additional 20 minutes.	HercepTest™ Interpretation Manual Effects of Insufficient Target Retrieval. (page 29)
	2b. Inadequate reagent incubation times.	Review Staining Procedure instructions.	See Instructions for Use
	2c. Inappropriate fixation method used.	Ensure that patient tissue is not over-fixed or that an alternative fixative was not used.	HercepTest™ Interpretation Manual Effects of Fixation. (page 28)
	2d. Excessive heating for more than one hour at $\geq 60^{\circ}\text{C}$ may cause a significant decrease or loss of the specific membrane-associated HER2 immunoreactivity.	Air dry the tissue sections at room temperature for a minimum of 12 hours or until dry. Alternatively, dry at $37^{\circ}\text{C}$ overnight or at $60^{\circ}\text{C}$ for a maximum of one hour. Drying of tissue sections at elevated temperatures must only be performed in a calibrated oven with uniform heat distribution.	HercepTest™ Interpretation Manual Effects of Excessive Tissue Drying. Loss of specific staining (page 30)

Problem	Probable Cause	Suggested Action	Reference
3. Excessive background staining of slides.	3a. Paraffin incompletely removed.	Use fresh clearing solutions and follow procedure as outlined in i Instructions for Use, section B.1	HercepTest™ Interpretation Manual Background Staining (page 21)
	3b. Starch additives used in mounting sections to slides.	Avoid using starch additives for adhering sections to glass sides. Many additives are immunoreactive.	
	3c. Slides not thoroughly rinsed.	Ensure that the Autostainer is properly primed prior to running. Check to make sure that adequate buffer is provided for entire run. Use fresh solutions of buffers and washes.	HercepTest™ Interpretation Manual Background Staining (page 21)
	3d. Sections dried during staining procedure.	Verify that the appropriate volume of reagent is applied to slides. Make sure the Autostainer is run with the hood in the closed position and is not exposed to excessive heat or drafts.	HercepTest™ Interpretation Manual Background Staining (page 21)
	3e. Sections dried while loading the Autostainer.	Ensure sections remain wet with buffer while loading and prior to initiating run.	HercepTest™ Interpretation Manual Background Staining (page 21)
	3f. Inappropriate fixation method used.	Ensure that approved fixative was used. Alternative fixative may cause excessive background staining.	HercepTest™ Interpretation Manual Background Staining (page 21)
	3g. Non-specific binding of reagents to tissue.	Check fixation method of the specimen and presence of necrosis.	HercepTest™ Interpretation Manual Background Staining (page 21)
	3h. Excessive heating of tissue. Refer to 2d.	Use corrective procedure for drying tissue sections.	
4. Tissue detaches from slides.	4a. Use of incorrect slides.	Use silanized slides, such as Dako Silanized Slides, Code S3003, SuperFrost Plus or poly-L-lysine coated slides.	
5. Excessively strong specific staining.	5a. Inappropriate fixation method used.	Ensure that only approved fixatives and fixation methods are used.	
	5b. Use of improper heat source for epitope retrieval, e.g. steamer, microwave oven or autoclave.	Ensure that only an approved procedure for target retrieval is applied. Refer to the Instructions for Use.	
	5c. Reagent incubation times too long.	Review Staining Procedure instructions.	
	5d. Inappropriate wash solution used.	Use only the Wash Buffer that is recommended for the kit.	



## Troubleshooting Guideline for HercepTest™

Problem	Probable Cause	Suggested Action	Reference
6. Weak staining of the 1+ Control Slide Cell Line.	6a. Incorrect epitope retrieval protocol followed.	Immerse the slides in the pre-heated Epitope Retrieval Solution. Bring temperature of the Epitope Retrieval Solution back to 95-99 °C and pre-treat for a full 40 minutes.	
	6b. Lack of reaction with Substrate-Chromogen Solution (DAB).	Ensure that the full 10 minute incubation time is used. Ensure that only one drop of DAB Chromogen was added to 1 mL of DAB Buffered Substrate.	
	6c. Degradation of Control Slide.	Check kit expiration date and kit storage conditions on outside of package.	
7. Other artifacts, miscellaneous.	7a. Heterogeneous Staining		HercepTest™ Interpretation Manual Heterogeneous Staining (page 19)
	7b. Cytoplasmic Staining		HercepTest™ Interpretation Manual Cytoplasmic Staining (page 23)
	7c. Edge Artifacts		HercepTest™ Interpretation Manual Edge Artifacts (page 24)
	7d. Retraction Artifacts		HercepTest™ Interpretation Manual Retraction Artifacts (page 25)
	7e. Thermal Artifacts		HercepTest™ Interpretation Manual Thermal Artifacts (page 26)
	7f. Crush Artifacts		HercepTest™ Interpretation Manual Crush Artifacts (page 27)
	7g. Decalcification Artifacts		HercepTest™ Interpretation Manual Decalcification Artifacts (page 27)

# Bibliography

- Alpert LI, Chao D: Detection of HER-2 overexpression: a new laboratory challenge. *Med Lab Observer*, June 1999, 29-37.
- Bartlett JMS, Going JJ, Mallon EA, Watters AD, Reeves JR, Stanton P, Richmond J, Donald B, Ferrier R, Cooke TG. Evaluating HER2 amplification and overexpression in breast cancer. *J Pathol* 2001; 195: 422-428
- Baselga J, Cortés J, Kim SB, Im SA, Hegg R, Im YH, et al. Pertuzumab plus trastuzumab plus docetaxel for metastatic breast cancer. *N Engl J Med* 2012;366:109-19.
- Birner P, Oberhuber G, Stani J, et al: Evaluation of the United States Food and Drug Administration-approved scoring and test system of HER2 protein expression in breast cancer. *Clin Cancer Res* 2001;7:1669
- Blackwell K., Mills D, Gianni L, et al. EMILIA: Primary results from EMILIA, a phase III study of trastuzumab emtansine (T-DM1) and lapatinib (L) in HER2-positive locally advanced or metastatic breast cancer (MBC) previously treated with trastuzumab (T) and a taxane. *J Clin Oncol*, 2012; 30 (suppl; abstr LBA1)
- Bloom Kenneth, Harrington Douglas, Enhanced Accuracy of HER-2/neu Immunohistochemical Scoring Using Digital Microscopy. *Am J Clin Pathol*. 2004; 121(5):619-630.
- Brown RE, Bernath AM, Lewis GO. HER-2/neu protein-receptor-positive breast carcinoma: An immunologic perspective. *Ann Clin Lab Sec* 2000; 30: 249
- Burris HA. Docetaxel (Taxotere) plus trastuzumab (Herceptin) in breast cancer. *Sem Oncol* 2001; 28: 38
- Burstein HJ, Kuter I, Campos SM, Gelman RS, Tribou L, Parker LM, Manola J, Younger J, Matulonis U, Bunnell CA, Partridge AH, Richardson PG, Clarke K, Shulman LN, Winer EP. Clinical activity of trastuzumab and vinorelbine in women with HER2-overexpressing metastatic breast cancer. *J Clin Oncol* 2001;19 (10): 2722-2730
- Burstein HJ: Recent Readings in the Oncology Literature- HER2 Testing: Defining the Gold-Standard. July 21, 1999 (Medscape Oncology Journal Scan Special Feature).
- Carlsson J, Nordgren H, Sjöström J, Wester K, Villman K, Bengtsson NO, Ostenstad B, Lundqvist H, Blomqvist C. HER2 expression in breast cancer primary tumours and corresponding metastases. Original data and literature review *Br J Cancer*. 2004;90(12):2344-8.
- Check W. More than one way to look for HER2. *CAP Today* 1999; 13(3) 1, 40-54.
- Couturier J, Vincent-Salomon A, Nicolas A, et al: Strong correlation between results of fluorescent in situ hybridization and immunohistochemistry for the assessment of the ERBB2 (HER-2/neu) gene status in breast carcinoma. *Mod Pathol* 2000;13:1238
- Dowsett M, Cooke T, Ellis I, Gullick WJ, Gusterson B, Mallon E, Walker R. Assessment of HER2 status in breast cancer: why, when and how? *Eur J Cancer* 2000; 36: 170
- Espinoza F, A Anguiano: The HercepTest assay: Another perspective (Letter+Reply). *J Clin Oncol* 1999;17(7): 2293-2294.
- Esteva FJ, Valero V, Booser D, Guerra LT, Murray JL, Pasztai L, Cristofanilli M, Arun B, Esmaili B, Fritsche HA, Sneige N, Smith TL, Hortobagyi GN. Phase II study of weekly docetaxel and trastuzumab for patients with HER-2-overexpressing metastatic breast cancer. *J Clin Oncol* 2002; 20:1800-1808
- Field AS, Charberlain NL, Tran D, Morey AL. Suggestions for HER2/neu testing in breast carcinoma, based on a comparison of immunohistochemistry and fluorescence in situ hybridization. *Pathology* 2001; 33: 278
- Fitzgibbons PL, Page DL, Weaver D, Thor AD, Allred DC, Clark GM, Ruby SG, O'Malley F, Simpson JF, Connolly JL, Hayes DF, Edge SB, Lichter A, Schnitt SJ. Prognostic factors in breast cancer: College of American Pathologists Consensus Statement 1999. *Arch Pathol Lab Med* 2000; 124: 966.
- Fornier M, Esteva FJ, Seidman AD. Trastuzumab in combination with chemotherapy for the treatment of metastatic breast cancer. *Sem Oncol* 2000; 27: 38.
- Hanna W, Kahn HJ, Trudeau M. Evaluation of HER-2/Erb-B2 on breast cancer cell lines: From bench to bedside. *Mod Pathol* 1999; 12(8): 827
- Hoang MP, Sahin AA, Ordonez NG, et al: HER-2/neu gene amplification compared with HER-2/neu protein overexpression and interobserver reproducibility in invasive breast carcinoma. *Am J Clin Pathol* 2000;113:852
- Jacobs TW, Barnes M, Yaziji H, et al.: HER2/neu protein expression in breast cancer determined by immunohistochemistry (IHC): A study of inter-laboratory agreement. *Mod Pathol* 1999 ;12:23A, (abstr).
- Jacobs TW, Gown AM, Yaziji H, Barnes MJ, Schnitt SJ: Comparison of fluorescence in situ hybridization and immunohistochemistry for the evaluation of HER-2/neu in breast cancer. *J Clin Oncol* 1999;17(7): 1974-1982.
- Jacobs TW, Gown AM, Yaziji H, Barnes MJ, Schnitt SJ: Specificity of HercepTest in determining HER-2/neu status of breast cancers using the United States Food and Drug Administration-approved scoring system. *J Clin Oncol* 1999;17(7):1983-1987.
- Koeppen HKW, Wright BD, Burt AD, Quirke P, McNicol AM, Dybdal NO, Sliwkowski MX, Hillan KJ. Overexpression of HER2/neu in solid tumours: an immunohistochemical survey. *Histopathol* 2001; 38: 96



- Lal P, Tan LK, Chen B. Correlation of HER-2 status with estrogen and progesterone receptors and histologic features in 3,655 invasive breast carcinomas. *Am J Clin Pathol*. 2005;123(4):541
- Lebeau A, Deimling D, Kaltz C, et al: Her-2/neu analysis in archival tissue samples of human breast cancer: comparison of immunohistochemistry and fluorescence in situ hybridization. *J Clin Oncol* 2001;19:354
- Lohrisch C, Piccart M. An overview of HER2. *Sem Oncol* 2001; 28, No 6, Suppl 18: 3-11
- Lottner C, Schwarz S, Diermeier S, Hartmann A, Knuechel R, Hofstaedter F, Brockhoff G. Simultaneous detection of HER2 neu gene amplification and protein overexpression in paraffin-embedded breast cancer. *J Pathol* 2005;205(5):577-84
- Maia DM: Immunohistochemical assays for HER2 overexpression (Letter). *J Clin Oncol* 17(5):1650, 1999.
- Masood S, Bui MM. Assessment of HER-2/neu overexpression in primary breast cancers and their metastatic lesions: An immunohistochemical study. *Ann Clin Laboratory Sci* 2000; 30 (3): 259.
- McNeil C: How should HER2 status be determined? *J Natl Cancer Inst* 91(2):111, 1999.
- Paik S, Bryant J, Tan-Chiu E, Romond E, Hiller W, Park K, Brown A, Yothers G, Anderson S, Smith R, Wickerham DL, Wolmark N. Real-world performance of HER2 testing — National Surgical Adjuvant Breast and Bowel Project Experience. *JNCI* 2002; 94: 852-854
- Parton M, Dowsett M, Ashley S, Hills M, Lowe F, Smith IE. High incidence of HER-2 positivity in inflammatory breast cancer. *Breast* 2004;13(2):97-103.
- Perez EA, Roche PC, Jenkins RB, Reynolds CA, Halling KC, Ingle JN, Wold LE. HER2 testing in patients with breast cancer: Poor correlation between weak positivity by immunohistochemistry and gene amplification by fluorescence in situ hybridization. *Mayo Clin Proc* 2002; 77: 148-154
- Persons DL, Bui MM, Lowery MC, et al: Fluorescence in situ hybridization (FISH) for detection of HER-2/neu amplification in breast cancer: a multicenter portability study. *Ann Clin Lab Sci* 2000;30:41
- Regitnig P, Schippinger W, Lindbauer M, Samonigg H, Lax SF. Change of HER-2/neu status in a subset of distant metastases from breast carcinomas. *J Pathol*. 2004 Aug;203(4):918-26.
- Roche PC, Suman VJ, Jenkins RB, Davidson NE, Martino S, Kaufman PA, Addo FK, Murphy B, Ingle JN, Perez EA. Concordance between local and central laboratory HER-2 testing in the breast intergroup trial N9831. *JNCI* 2002; 94: 855-857
- Roche PC, Ingle JN: Increased HER2 with U.S. Food and Drug Administration-approved antibody. *J Clin Oncol* 17:434, 1999 (letter)
- Ropke M, Askaa J, Key M. HER2/neu. *CAP Today* 1999; 13 (7):11-12
- Ross J, Fletcher JA. The HER-2/neu oncogene: prognostic factor, predictive factor and target for therapy. *Sem Canc Biol* 1999; 9: 125.
- Rudlowski C, Friedrichs N, Faridi A, Fuzesi L, Moll R, Bastert G, Rath W, Buttner R. Her-2/neu gene amplification and protein expression in primary male breast cancer. *Breast Cancer Res Treat*. 2004;84(3):215-23.
- Sahin AA. Biologic and clinical significance of HER-2/neu (cerbB-2) in breast cancer. *Adv Anat. Pathol*. 2000; 7 (3): 158.
- Simon R, Nocito A, Hubscher T, Bucher C, Torhorst J, Schraml p, Bubendorf L, Mihatsch MM, Moch H, Wilber K, Schotzau A, Kononen J, Sauter G. Patterns of HER-2/neu amplification and overexpression in primary and metastatic breast cancer. *J Natl Cancer Inst* 2001; 93: 1141
- Tripathy D, Plante M: HER-2 as a Predictive Marker — Data from CALGB, NSABP, and SWOG. San Antonio Breast Cancer Symposium, December 12, 1998 (Medscape Daily Summary).
- Van Poznak C, Tan L, Panageas KS, Arroyo CD, Hudis C, Norton L, Seidman AD. Assessment of molecular markers of clinical sensitivity to single-agent taxane therapy for metastatic breast cancer. *J Clin Oncol*. 2002; 20 (9): 2319
- Vera-Roman JM, Rubio-Martinez LA. Comparative assays for the HER-2/neu oncogene status in breast cancer. *Arch Pathol Lab Med*. 2004;128(6):627-33.
- Wang S, Saboorian MH, Frenkel EP, Haley BB, Siddiqui MT, Gokaslan S, Wians FH, Hynan L, Ashfaq R. Assessment of HER-2/neu status in breast cancer: Automated cellular imaging system-assisted quantitation of immunohistochemical assay achieves high accuracy in comparison with fluorescence in situ hybridization assay as the standard. *Am J Clin Pathol* 2001; 116: 495
- Wisecarver JL: HER-2/neu testing comes of age. *Am J Clin Pathol* 1999; 111(3):299-301.
- Wolff AC, Hammond ME, Hicks DG, Dowsett M, McShane LM, Allison KH, et al. Recommendations for human epidermal growth factor receptor 2 testing in breast cancer: American Society of Clinical Oncology/College of American Pathologists clinical practice guideline update. *J Clin Oncol* 2013; 31:3997-4013.

#### Acknowledgements

Dako would like to thank Dr. Froilan Espinoza at Quest Diagnostics and Dr. Jim Thompson at Impath Laboratories for their generosity in contributing to this project. Impath Laboratories and Quest Diagnostics process a large volume of HercepTest™ slides every month. Dr. Espinoza and Dr. Thompson contributed by offering their expertise and providing many of the images throughout this manual.





# Relentless in our commitment to fighting cancer. Together.



An Agilent Technologies Company

Corporate Headquarters  
Denmark  
+45 44 85 95 00

[www.dako.com](http://www.dako.com)

Represented in more  
than 100 countries

Australia  
+61 2 9922 0700

Austria  
+43 1 408 43 34 0

Belgium  
+32 (0) 16 38 72 20

Brazil  
+55 11 50708300

Canada  
+1 905 335 3256

China  
+86 21 3612 7091

Denmark  
+45 44 85 97 56

Finland  
+358 9 348 73 950

France  
+33 1 64 53 61 44

Germany  
+49 40 69 69 470

Ireland  
+353 1 479 0568

Italy  
+39 02 58 078 1

Japan  
+81 3 5802 7211

Korea  
+82 2 402 6775

The Netherlands  
+31 20 42 11 100

Norway  
+47 23 14 05 40

Poland  
+48 58 661 1879

Spain  
+34 93 499 05 06

Sweden  
+46 8 556 20 600

Switzerland  
+41 41 760 11 66

United Kingdom  
+44 (0)1 353 66 99 11

United States of America  
+1 805 566 6655