

# Mi1200

## SYNCHRONY Surgical Guideline



hearLIFE



# Introduction

The MED-EL Cochlear Implant System serves to restore hearing sensations through electrical stimulation of the auditory nerve. It is the result of many years of research at leading technical institutions throughout the world.

MED-EL cochlear implants are manufactured to the highest quality standards in order to ensure long term reliability. All materials used in the implant have been rigorously tested for biocompatibility, durability and reliability. MED-EL applies a quality management system that meets all EN ISO 13485:2003 requirements and complies with US Quality System Regulations and Canadian Medical Device regulations (CAN/CSA ISO 13485-2003). Components of the MED-EL Cochlear Implant System meet the requirements for AIMD 90/385/EEC and MDD 93/42/EEC.

This Surgical Guideline describes proper techniques for implanting the Mi1200 SYNCHRONY Cochlear Implant (hereafter referred to as the SYNCHRONY). It serves as additional information for professionals and should not be used as an "Instructions for Use".

The information in this brochure is believed to be true and correct. However, specifications are subject to change without notice.

Not all products represented on these materials are currently approved or available in all markets. For country specific information please see the applicable "Instruction for Use" delivered with the implant system.

# Table of contents

I. Patient selection and evaluation	2
Indication	2
Selection and Evaluation	2
II. Technical description of the implant	3
Performance Characteristics	4
Implant Variants	4
III. Surgical tools	9
Surgical Kit for the SYNCHRONY Cochlear Implant	9
Insertion Test Tools	14
V. Surgical procedure	16
STEP 1: Prepare Patient	16
STEP 2: Mark Implant Position	17
STEP 3: Plan Incision	18
STEP 4-A: Open Skin Flap	19
STEP 4-B: Skin Flap Thickness	20
STEP 5: Check Position of Implant and Electrode Lead	21
STEP 6: Drill Mastoidectomy and Posterior Tympanotomy	22
STEP 7: Drill Stimulator Bed and Electrode Channel	24
STEP 8 – VARIANT 1: Preparation for a Round Window opening	25
STEP 8 – VARIANT 2: Preparation for a Cochleostomy	27
STEP 9: Select Appropriate Electrode Variant	29
STEP 10: Immobilize the Implant	31
STEP 11: Opening the Cochlea	32
STEP 12: Insert the Electrode Array	33
STEP 13-A: Seal Cochlear Opening	36
STEP 13-B: Secure Electrode Lead	37
STEP 14: Intra-operative Recordings	39
STEP 15: Close Wound	40
Appendix	41
MRI CAUTION	41
Magnet Removal Procedure	43
X-rays	48
Explanting the Device	48
MED-EL Surgical Videos	49
Hearing Preservation Surgical Technique	50
Literature	52

# I. Patient selection and evaluation

## Indication

The MED-EL Cochlear Implant System is intended to evoke auditory sensations via electrical stimulation of the auditory pathways. It is designed for severely to profoundly hearing impaired individuals who obtain little or no benefit from acoustic amplification in the best aided condition.

Additionally the MED-EL Cochlear Implant System used in combination with the implant variant +FLEX24 or +FLEX20 is intended to evoke auditory sensations via electrical stimulation or via combined electric-acoustic stimulation (EAS) of the auditory pathways for partially deaf individuals, who obtain benefit from acoustic amplification in the lower frequencies only.

The MED-EL Cochlear Implant System is also intended to evoke auditory sensations via electrical stimulation of the auditory pathways for individuals with single-sided deafness, which is defined as severe to profound hearing impairment in one ear and normal hearing or mild to moderate hearing impairment in the other ear.

motivated and understand the importance of returning to the implant centre for regular audio processor programming, training, and assessment sessions.

The medical evaluation prior to cochlear implant surgery serves to:

- assess the candidate's health status and ability to undergo surgery
- verify the absence of disease and infection of the outer and middle ear
- screen for cochlear obliteration and other obstacles to electrode insertion
- rule out central auditory lesions and verify a functional auditory nerve

The above evaluations usually involve an otologic/otoscopic examination and a CT scan and/or MRI. If there are concerns about the integrity of the upper auditory pathways and auditory lesions, an MRI is necessary.

It is important to realise that there are a variety of conditions that predispose a person to contracting bacterial meningitis irrespective of cochlear implantation, such as: malformations of the inner ear, history of recurrent meningitis, the presence of CSF leaks, etc. There is no evidence that implantation of a MED-EL device increases the risk for postoperative meningitis. MED-EL encourages all cochlear implant candidates and recipients, especially individuals with cochlear malformations and other risk factors, to discuss with their physician whether vaccination may be appropriate for them. The immunisation status of all cochlear implant candidates should be determined prior to surgery. Vaccination may reduce the risk of infection.

## Selection and Evaluation

Patients should fulfil the audiological criteria of their respective country for open-set sentence testing and open-set monosyllabic words when tested with hearing aids. MED-EL strongly recommends the use of optimally fitted hearing aids for a minimum of three months before deciding to pursue a cochlear implant. In cases of ossification or deafness due to infectious disease, there may be no need to try a hearing aid, and implantation should generally not be delayed.

A complete cochlear implant evaluation protocol should include an audiologic assessment, a medical/surgical evaluation, counselling sessions and, when possible, a psychological assessment. To obtain the optimal benefit from the implant, candidates should be sufficiently



## II. Technical description of the implant

The SYNCHRONY is the implantable part of the MED-EL Cochlear Implant System and can only be used together with compatible MED-EL external components.

The device consists of a stimulator, a coil with a removable magnet within its centre, a reference electrode, an EAP reference electrode and an active electrode permanently attached to the stimulator. The active electrode can be of different types, thus resulting in different implant variants (implant family SYNCHRONY PIN). This device is intended to be implanted by adequately trained and experienced surgeons only.

The SYNCHRONY has been designed according to the highest safety and reliability standards. All materials used in the construction of the SYNCHRONY have been extensively tested for biological compatibility and durability. The power required by the implant is transmitted from the external audio processor through the intact skin via an inductive link. The implant therefore contains no batteries or other components that require replacement.

The implant offers a stimulation mode and a telemetry mode. Stimulation sequences of biphasic and triphasic pulses can be delivered sequentially or simultaneously on two or more channels. In telemetry mode the device allows a functional check about the technical status of the implant including communication over the transcutaneous link as well as the assessment of the electrode impedances and recording of the electrically evoked compound action potential of the hearing nerve.

The electronics of the SYNCHRONY contain a powerful custom-made circuit that is capable of processing large amounts of information at a very rapid rate. It can stimulate at 50,704 pulses per second. This capability makes the implant compatible with a wide range of pulsatile processing strategies and future developments in speech processing. A telemetry feature enables the clinic to verify the functional status of the implant within a matter of seconds. For added safety, each output has a capacitor to prevent any possible leakage of DC current to the auditory nerve.

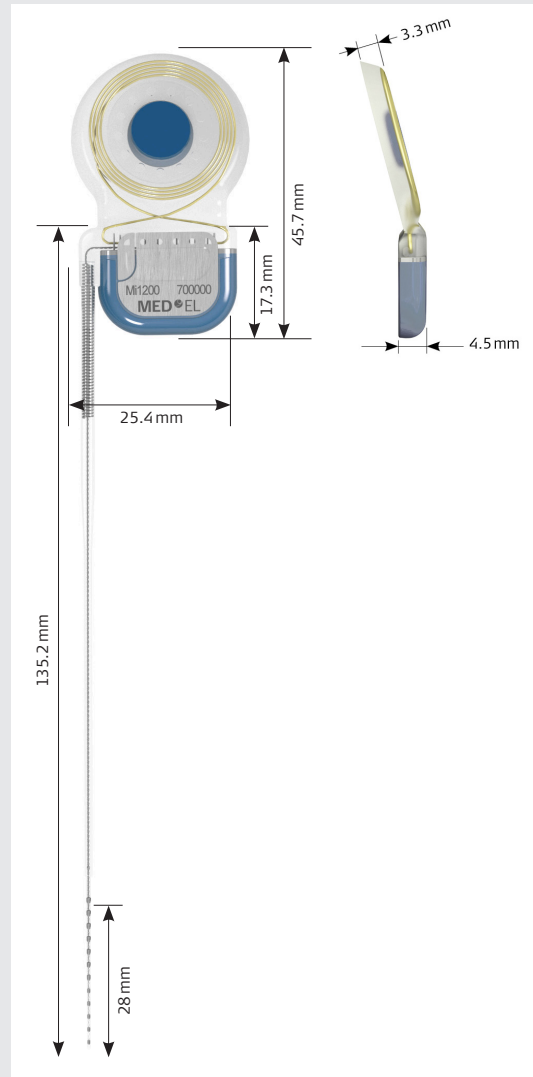


Figure 1 SYNCHRONY Cochlear Implant (~ dimensions in mm, typical values)

## Performance Characteristics

- Output characteristics of a stimulation signal on a 1 kOhm resistor:  
Maximum current amplitude:  
Median value = 1250  $\mu$ A, range = 500  $\mu$ A  
Maximum pulse width:  
Median value = 203.8  $\mu$ s, range = 8.2  $\mu$ s
- The impedance measurement accuracy is typically better than 5%.
- When keeping to the safety guidelines the implant is conditionally MRI safe for MR scanner field strengths of 0.2 Tesla, 1.0 Tesla, 1.5 Tesla and 3.0 Tesla.
- There are no default factory settings of the implant system.
- Proper functioning of the implantable part of the CI system can be checked by performing telemetry (refer to MED-EL application software user manual).
- The implant has 24 independent current sources stimulating 12 independent electrode channels in monopolar mode.
- The implant has a mass of 7.6 g (typical value).
- The volume of the implant without electrode is 3.7 cm<sup>3</sup>.
- The electrode is made of medical grade silicone, platinum (electrode contacts) and platinum/iridium (90/10) wires and nitinol.
- All electrode variants have a straight and flexible design. The electrode does not deliver any medicinal substances.
- Geometric surface area of the stimulation reference electrode = 50 mm<sup>2</sup>.
- Following materials are in direct contact with human tissue: medical grade silicone, platinum, iridium and parylene c.

## Implant Variants<sup>\*</sup>

Cochleae may differ significantly in size and shape from one another as can individual cochlear duct lengths. MED-EL offers the largest selection of electrode arrays for each implant variant. Please see Section V, Step 9, "Select Appropriate Electrode Variant" for the circumstances in which each variant should be used.

### FLEXSOFT Electrode Array

**Order number: 31091**

The FLEXSOFT Electrode Array (see Figure 2) is 31.5 mm long featuring FLEX tip technology for increased mechanical flexibility and enabling CCC (Complete Cochlear Coverage). The contacts for the 12 channels are arranged as 5 single contacts at the apical array end and 7 contact pairs at the base with a 2.4 mm spacing between each channel. The specially designed electrode tip offers increased mechanical flexibility for reduced insertion force. The marker ring is located 31.5 mm from the electrode tip and indicates the deepest insertion. Near the marker ring, the electrode lead features an additional marker dot on the same side of the array as the single apical contacts. The marker allows the surgeon to ensure appropriate alignment of the single contacts toward the modiolus.

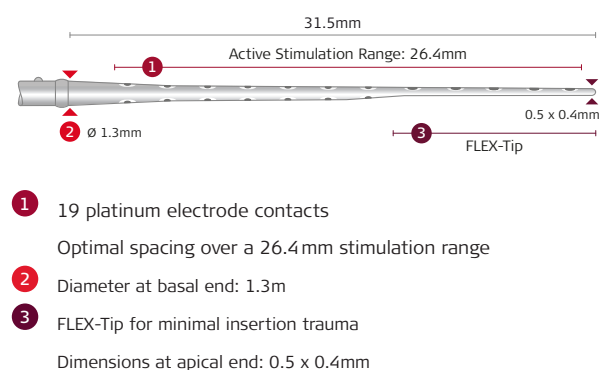



Figure 2 FLEXSOFT Electrode Array

<sup>\*</sup> Implant variants availability is subject to regulatory approval

## FLEX28 Electrode Array

Order number: 31093

The FLEX28 Electrode Array (see Figure 3) is 28 mm long featuring FLEX tip technology suitable for 96 % of all normal cochlear duct lengths. The contacts for the 12 channels are arranged as 5 single contacts at the apical array end and 7 contact pairs at the base with a 2.1 mm spacing between each channel. The specially designed electrode tip offers increased mechanical flexibility for reduced insertion force. The marker ring is located 28 mm from the electrode tip and indicates the deepest insertion. Near the marker ring, the electrode lead features an additional marker dot on the same side of the array as the single apical contacts. The marker allows the surgeon to ensure appropriate alignment of the single contacts toward the modiolus.




- 1 19 platinum electrode contacts  
Optimal spacing over a 23.1 mm stimulation range
- 2 Diameter at basal end: 0.8mm
- 3 FLEX-Tip for minimal insertion trauma  
Dimensions at apical end: 0.5 x 0.4mm

Figure 3 FLEX28 Electrode Array

## FLEX24 Electrode Array

Order number: 31089

The FLEX24 Electrode Array (see Figure 4) is 24 mm long featuring FLEX tip technology and designed for combined Electric Acoustic Stimulation (EAS) less than 1.5 turns. The contacts for the 12 channels are arranged as 5 single contacts at the apical array end and 7 contact pairs at the base with a 1.9 mm spacing between each channel. The specially designed electrode tip offers increased mechanical flexibility for reduced insertion force. The marker ring is located 24 mm from the electrode tip and indicates the deepest insertion. Near the marker ring, the electrode lead features an additional marker dot on the same side of the array as the single apical contacts. The marker allows the surgeon to ensure appropriate alignment of the single contacts toward the modiolus.



- 1 19 platinum electrode contacts  
Optimal spacing over a 20.9 mm stimulation range
- 2 Diameter at basal end: 0.8mm
- 3 FLEX-Tip for minimal insertion trauma  
Dimensions at apical end: 0.5 x 0.3mm

Figure 4 FLEX24 Electrode Array

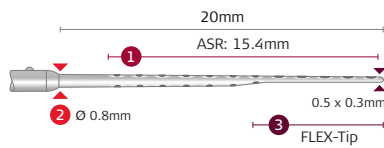
EAS

EAS SURGICAL TRAINING RECOMMENDED

## FLEX20 Electrode Array

Order number: 31113

The FLEX20 Electrode Array (see Figure 5) is 20mm long featuring FLEX tip technology and designed for combined Electric Acoustic Stimulation (EAS). The contacts for the 12 channels are arranged as 5 single contacts at the apical array end and 7 contact pairs at the base with a 1.4mm spacing between each channel. The specially designed electrode tip offers increased mechanical flexibility for reduced insertion force. The marker ring is located 20mm from the electrode tip and indicates the deepest insertion. Near the marker ring, the electrode lead features an additional marker dot on the same side of the array as the single apical contacts. The marker allows the surgeon to ensure appropriate alignment of the single contacts toward the modiolus.



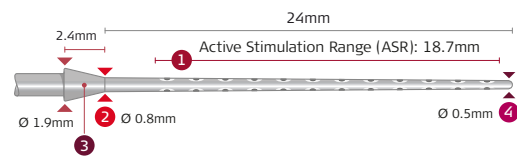
- 1 19 platinum electrode contacts  
Optimal spacing over a 15.4mm stimulation range
- 2 Diameter at basal end: 0.8mm
- 3 FLEX-Tip for minimal insertion trauma  
Dimensions at apical end: 0.5 x 0.3mm

Figure 5 FLEX20 Electrode Array

## FORM24™

Order Number: 31089

The FORM24 Electrode Array\* (see Figure 6) is 24 mm long designed for open (no obliteration or ossification) or malformed cochleae, especially Type II malformations. It features 12 evenly spaced electrode pairs spaced over 18.7 mm, with 1.7 mm spacing between each contact pair. The FORM24 electrode array features an integrated SEAL function designed to aid closing off the cochlear opening. SEAL is a 2.4 mm conical thickening located at the basal end of the array designed to help control the leakage of cerebrospinal fluid (CSF) during surgery, also known as 'gusher'.



- 1 24 platinum electrode contacts  
Optimal spacing over a 18.7mm stimulation range
- 2 Diameter at basal end: 0.8mm
- 3 SEAL
- 4 Diameter at apical end: 0.5mm

Figure 6 FORM24™

EAS

EAS SURGICAL TRAINING RECOMMENDED

\* Electrode development was in close collaboration with Prof. Levent Sennaroglu, Department of Otolaryngology, Hacettepe University Medical Faculty, Turkey

## FORM 19™

Order Number: 31098

The FORM19 Electrode Array\* (see Figure 7) is 19 mm long designed intended to be used in cochleae with malformation, especially Type I and Type III, obliteration, or ossification. It features 12 evenly spaced electrode pairs spaced over 14.3 mm, with 1.3 mm spacing between each contact pair. The FORM19 electrode array features an integrated SEAL function designed to aid closing off the cochlear opening. SEAL is a 2.4 mm conical thickening located at the basal end of the array designed to help control the leakage of cerebrospinal fluid (CSF) during surgery, also known as 'gusher'.

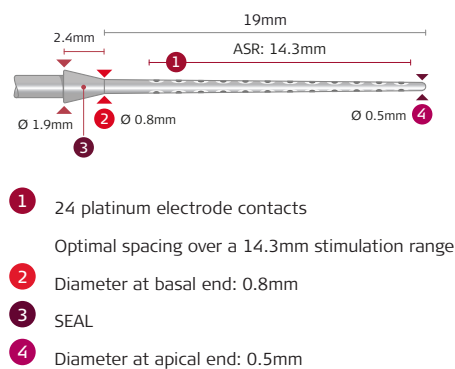


Figure 7 FORM19™

## Standard Electrode Array

Order number: 31084

The Standard Electrode Array (see Figure 8) is 31.5 mm long and designed for long cochlear duct lengths. Contacts are spaced over 26.4 mm with 2.4 mm spacing between each contact pair. The electrode's length allows insertion into the scala tympani and stimulation of the cochlear canal to the fullest extent possible. The array features a marker ring 31.5 mm from the apex that is used to seal and to indicate maximum electrode insertion. The diameter of the array increases to 1.3 mm at the proximal thicker part of the array just before the marker ring.

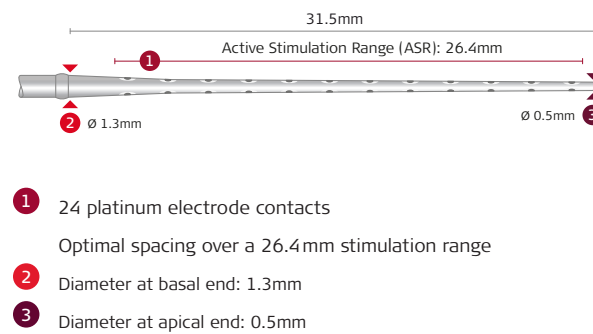



Figure 8 Standard Electrode Array

\* Electrode development was in close collaboration with Prof. Levent Sennaroglu, Department of Otolaryngology, Hacettepe University Medical Faculty, Turkey

## Medium Electrode Array

Order number: 31087

The Medium Electrode Array (see Figure 9) is 24 mm long and designed for cases where deep insertion is not desired or is not possible due to anatomic restrictions. It features 12 evenly spaced electrode pairs spaced over 20.9 mm, with 1.9 mm spacing between each contact pair. Note that the Medium Electrode Array is not inserted to the marker ring.



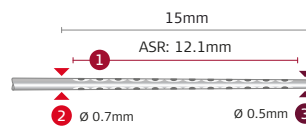
- 1 24 platinum electrode contacts  
Optimal spacing over a 20.9 mm stimulation range
- 2 Diameter at basal end: 0.8mm
- 3 Diameter at apical end: 0.5mm

Figure 9 Medium Electrode Array

## Compressed Electrode Array

Order number: 31097

The Compressed Electrode Array (see Figure 10) is 15 mm long and designed for partial ossification or malformation of the cochlea. It features 12 pairs of contacts spaced closer together in the apical end of the array. The contacts are spaced over 12.1 mm, with 1.1 mm between each contact pair. Note that the Compressed Electrode Array is not inserted to the marker ring.



- 1 24 platinum electrode contacts  
Optimal spacing over a 12.1 mm stimulation range
- 2 Diameter at basal end: 0.7mm
- 3 Diameter at apical end: 0.5mm

Figure 10 Compressed Electrode Array

# III. Surgical tools

Note that the surgical tools supplied by MED-EL should not be modified in any way. Modification of any of the tools is done at the surgeon's own risk.

Detailed instruction of the reprocessing process and the individual preparation before cleaning the tools can be found in the appropriate Instruction for Use.

## Surgical Kit for the SYNCHRONY Cochlear Implant

The MED-EL Surgical Kit is a collection of tools for implantation of the SYNCHRONY Cochlear Implant.

The following tools are included in the SYNCHRONY Surgical Kit:

	Order number:
Mi1200 Implant Template	Shipped with the implant
Processor Template	01557
Skin Flap Gauge 6	03543
Surgical Claw Angled	00284
Micro Forceps Angled	05761, 05777, 05778

### Mi1200 Implant Template

Shipped with the implant

This silastic template is used to assess the size and the position of the implant on the skull.

This tool is delivered in a sterile packaging and is a single-use device only.



Figure 11 Mi1200 Implant Template

## Processor Template

Order number: 01557

The Processor Template (TEMPO+/OPUS template) shows the minimum spacing which must remain free behind the ear so that the external coil and the BTE Audio Processor do not interfere with each other when worn by the patient post-operatively.

This tool is a re-usable surgical instrument for transient use made from medical grade stainless steel. The device is delivered non-sterile.



Figure 12 Processor Template

## Skin Flap Gauge 6

Order number: 03543

The Skin Flap Gauge 6 is used to evaluate the thickness of the skin flap in the area covering the cochlear implant. A skin flap thickness of 6 mm or less is necessary for a good magnetic hold and optimal signal transmission. Thick skin flaps should be reduced to 6 mm or less.

This tool is a re-usable surgical instrument for transient use made from medical grade stainless steel. The device is delivered non-sterile.



Figure 13 Skin Flap Gauge 6



## Surgical Claw Angled

Order number: 00284

The Surgical Claw Angled can help to position and insert the electrode array into the cochlea. The tip of this instrument is slightly bent for better visualization during electrode insertion.

This tool is a re-usable surgical instrument for transient use made from medical grade stainless steel. The device is delivered non-sterile.

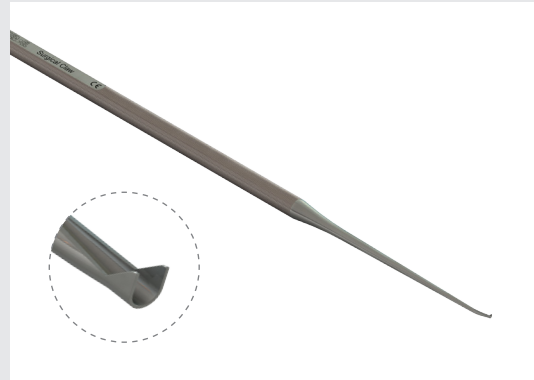


Figure 14 Surgical Claw Angled

## Micro Forceps Angled

Order number: 05761 Right Angled & Left Angled

05777 Right Angled

05778 Left Angled

The Micro Forceps Left Angled and the Micro Forceps Right Angled are used to grip, hold and insert the electrode into the cochlea without damaging it. It is the surgeon's preference which angled Micro Forceps to use to insert the electrode array in either the left or the right ear. In the closed position, the tips of the forceps are parallel to each other, separated by a distance of 0.25 mm.

This tool is a re-usable surgical instrument made from medical grade stainless steel. The device is delivered non-sterile.

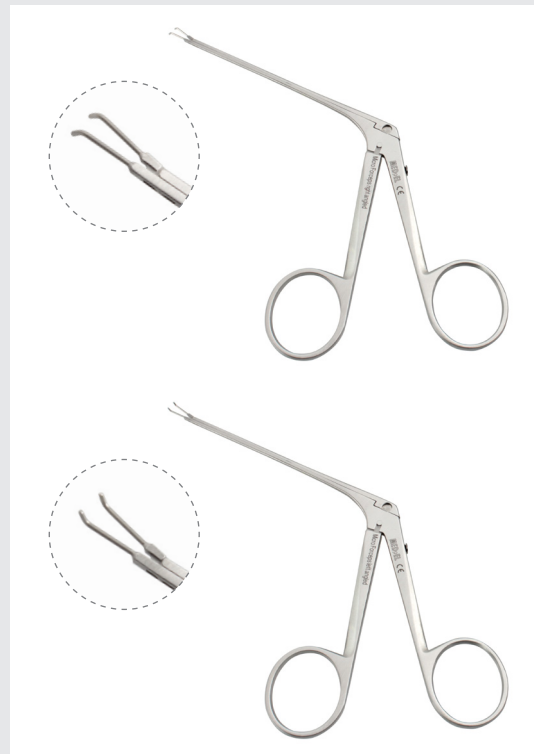

Figure 15 Micro Forceps Right Angled  
Micro Forceps Left Angled

The following tools are additions to the surgical kit and may be ordered separately:

### FENTEXmedical Forceps

FENTEXmedical GmbH is specialized in the development, manufacturing and marketing of surgical instruments and visualization systems for ENT, Head & Neck and Facial Surgery.

Basic description of the device:

CI Electrode Insertion Forceps L=155 mm, with longitudinal groove, for electrodes with a basal diameter in the range 0.8 – 1.3 mm

FENTEXmedical forceps have been successfully tested at headquarters with all MED-EL electrode arrays. This surgical tool is no MED-EL product and may therefore be ordered directly at your local FENTEXmedical distributor.

<http://www.fentexmedical.com/>

### Surgical Claw Straight

Order number: 07711

The Surgical Claw can help to position and insert the electrode array into the cochlea. The tip of this instrument is straight.

This tool is a re-usable surgical instrument made from medical grade stainless steel. The device is delivered non-sterile.

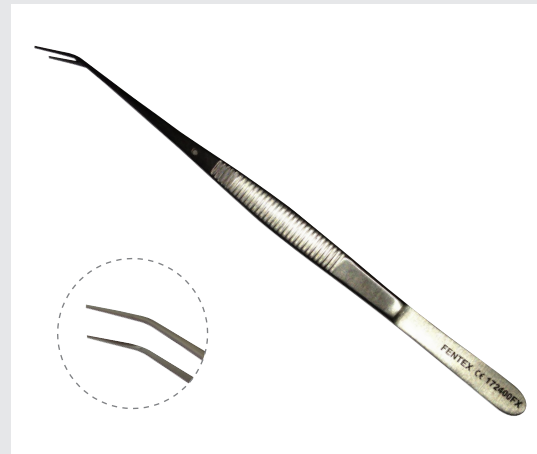

Figure 16 FENTEXmedical Forceps



Figure 17 Surgical Claw Straight

## Magnet Replacement Kit

Order number: 09693

Consisting of:

### Non-Magnetic Spacer Ms010107

The Non-Magnetic Spacer (see Figure 18) is intended to be used as placeholder for the regular implant magnet of the Mi1200 Hearing Implant during MRI procedures, when a reduced image artifact is desirable.

### Replacement Magnet Ms010108

The Replacement Magnet (see Figure 19) is intended to be used after an MRI, as replacement of the original implant magnet of the Mi1200 Hearing Implant and to restore full functionality of the Mi1200 Hearing Implant.

## Magnet Tool Kit

Order number: 09734

Consisting of:

### Magnet Removal Tool Ms050206

### Magnet Insertion Tool Ms050205

The Magnet Removal Tool (see Figure 20) is for removal of the MED-EL removable implant magnet and the Non-Magnetic Spacer.

The Magnet Insertion Tool (see Figure 21) is for insertion of the Non-Magnetic Spacer and the Replacement Magnet.

The instruments are made of surgical grade stainless steel. The devices are delivered non-sterile



Figure 18  
Non-Magnetic Spacer



Figure 19  
Replacement Magnet




Figure 20 Magnet Removal Tool




Figure 21 Magnet Insertion Tool

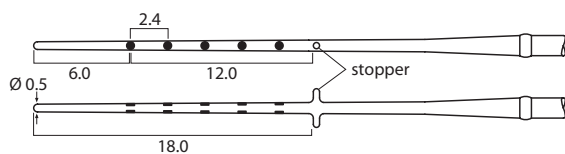
## Insertion Test Tools

They are primarily used when ossification or fibrosis is suspected to aid the surgeon in determining which electrode variant to use (e.g. for detailed dimensions please see section II Implant Variants).

### Insertion Test Device (ITD)

Order number: 02081

The ITD is similar to the Standard Electrode Array in dimension and shape. It has a stopper at 18.0 mm and 5 pairs of markers to help determine insertion depth up to a maximum of 18.0 mm. The Insertion Test Device is delivered in sterile packaging and is a single-use device only.



Typical dimensions in mm

Figure 22 Insertion Test Device

Contact spacing: 2.4 mm  
 Markers: 2x5  
 Max. insertion depth: 18.0 mm

### Insertion Electrode (IE)

With the Insertion Electrode (IE) the surgeon can establish whether the cochlear lumen is obstructed or if it is freely accessible up to different insertion depths depending upon the considered electrode variant planned for the implantation.

The Insertion Electrodes are delivered in sterile packaging and are single-use devices only.

Order Number	Electrode Array
08255	FLEXSOFT
08348	FLEX28
08257	FLEX24
08254	Standard
08256	Medium
08258	Compressed

## IV. General remarks about the surgery

- Prophylactic use of antibiotics is recommended for all patients unless medically contraindicated.
- Facial nerve monitoring is recommended. When carried out, neuromuscular blockage should be avoided.
- Evaluation of possible electrode insertion length for the individual patient should be done prior to the surgery. This can be performed by a standard X-ray or a CT scan.
- Sterility of the implant must be ensured at all times.
- The implant must never be dropped onto a hard surface; damage to the implant or electrodes during the operation will invalidate the warranty.
- Before opening the implant box a telemetry should be done to check the function of the implant inside the box.
- In cases where the patient has a thick skin flap, the flap should be thinned to no more than 6mm. Use the Skin Flap Gauge 6 to accurately determine skin flap thickness.
- The area of the temporal bone on which the stimulator will be placed, shall be flattened in order to ensure that the implant is sufficiently immobilized.
- The electrode lead should be placed in a ramp-like bony channel without sharp edges to protect it against postoperative movement and excessive mechanical impact.
- Do not place sutures over the active electrode lead.
- Only surgical instruments approved by MED-EL should be used during the insertion process, other instruments (probes, hooks, forceps, tweezers, etc.) can damage the electrode array.
- The electrode array should be inserted as far as possible or planned, according to the individual electrode insertion length, into the cochlea without compressing the array, or using excessive force.
- After the electrode array has been inserted into the cochlea, small pieces of temporalis fascia should be placed around the electrode array at the entrance to the cochlea to secure the electrode array and to seal the cochlea opening.
- The excess electrode lead must be looped and secured with caution in the mastoid cavity. It must be secured under the cortical overhang so that the electrode array will not migrate out of the cochlea or be subject to external pressure that could cause movement and subsequent damage to the electrical connections.
- Monopolar electrosurgical instruments must not be used in the head and neck region. If bipolar electrosurgical instruments must be used, the tips of the cautery must be kept at least 3 cm away from the stimulator, coil, and all areas of the electrode.
- A paper on pathomechanisms, clinical symptoms, conservative and surgical treatments in cases of meningitis may be useful additional reading. (Arnold et al, ORL 2002;64:382-389).

## V. Surgical procedure

The SYNCHRONY Cochlear Implant can be implanted using a small incision, however, for demonstration purposes only, the following illustrations include an enlarged incision area. Additionally, some of the medical illustrations are schematic and can differ from a patient's anatomical situation.

Every CI surgery should be performed as atraumatically as possible so that residual hearing can be preserved. The following surgical procedure will ensure that. Additional important surgical steps for EAS patients can be found in the appropriate EAS Infobox. Summarised EAS information can be found in the appendix.

### STEP 1: Prepare Patient

As a prophylactic measure, intravenous antibiotics should be given 1/2 to 1 hour before the incision is made.

After the patient has been anaesthetised, the incision area should be shaved. Usually an area including the incision line and the area between the incision and the pinna is shaved. Some surgeons choose to shave only the area over the predetermined line of the incision, and they recommend a margin of at least 2 cm around the incision. Meticulous care should be taken to ensure that the site is well cleansed. After cleansing and draping the site, inject local anaesthetics containing vasoconstrictors, e.g. adrenaline 1:200,000 up to 20 mls.

#### EAS

- Please ensure that corticosteroids (crystalline triamcinolone solution or dexamethasone), intravenous corticosteroids, and hyaluronic acid are all available for the surgery.
- Administer intravenous antibiotics from the Cephalosporin group approximately half an hour before the skin incision.

## STEP 2: Mark Implant Position

Place the Processor Template behind the ear and position the Mi1200 Implant Template. There are various orientation options. A suggested orientation for each ear is shown in Figure 23 and Figure 24, but the orientation depends on various factors, like e.g. the curvature of the skull.

Position the implant template in such a way that the SYNCHRONY Cochlear Implant will be in the hair bearing area. The lower part of the stimulator should be under or close to the temporal line, with an angle between 30° and 60°. The electrode exits on the lateral side of the implant. Therefore the electrode lead comes out superiorly for the left ear and inferiorly for the right ear.

Particular attention should be paid to the placement of the electrode lead on the skull. The position of the reinforced part of the electrode lead should be selected to facilitate the placement of the entire length of the electrode in a recessed channel. This ensures that the reinforced part of the electrode lead does not protrude into the mastoidectomy.

Once the implant template is in place, surgical ink may be used to mark its position on the surface of the skin. Surgeons may choose to transpose the position of the implant template onto the surface of the bone by using a hypodermic needle inserted perpendicularly to the skin at points along the side of the implant template.

When implanting a patient bilateral care should be taken of the placement of the implants. In particular the second side should be placed specifically to match the location of the first to give symmetric appearance of the external part. The skull curvature and pinna position needs to be taken into consideration when placing the second implant similar to the contralateral side.

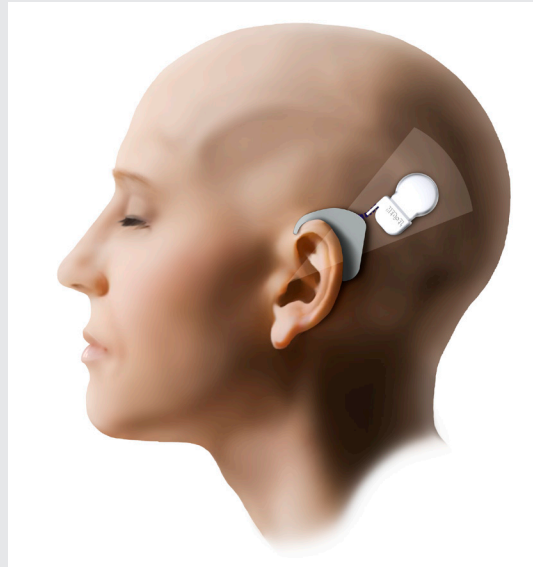

Figure 23 Suggested orientation of the templates, left side

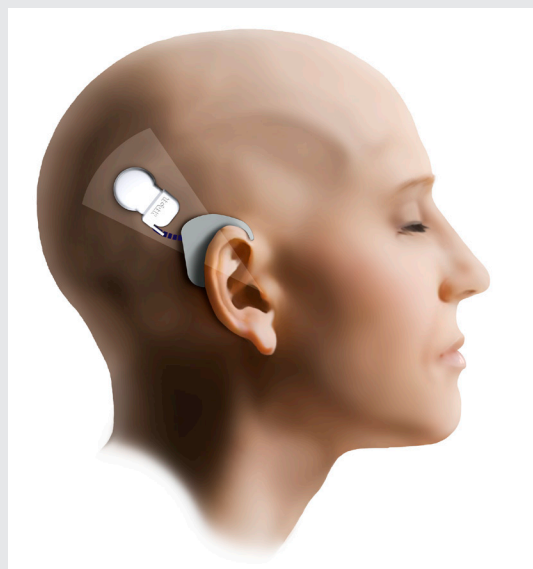

Figure 24 Suggested orientation of the templates, right side

## STEP 3: Plan Incision

Choose the line of incision so that a well vascularised skin flap results. Make the incision 1-2 cm from the implant to ensure that the scar will not lie directly over the body of the implant. Incise the tissue with a scalpel and use bipolar electrocoagulation for hemostasis.

An example of a commonly used postaural incision is shown in Figure 25 and Figure 26. Postaural incisions start in the sulcus behind the pinna and extend posteriorly.

For greater mastoid bone exposure, each of these incisions can be extended posteriorly in the shape of an arc.

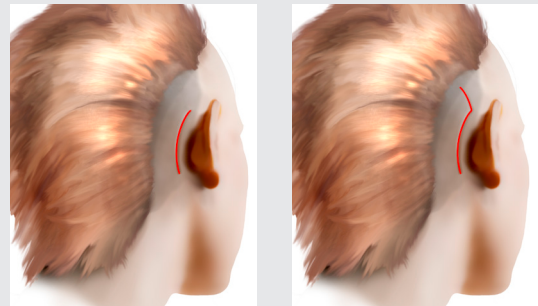


Figure 25 Minimal incision (left picture) and lazy "S" incision (right picture) – right ear

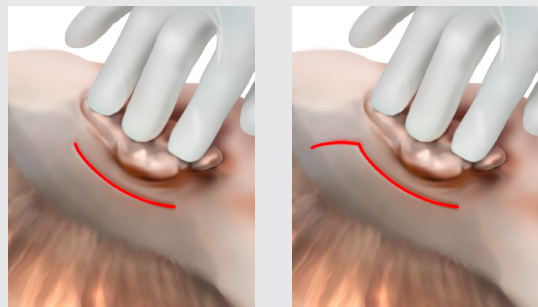


Figure 26 Minimal incision (left picture) and lazy "S" incision (right picture) – right ear – close up



## STEP 4-A: Open Skin Flap

The incision is made and the wound is held open by retractors. At all times care should be taken to ensure that the flap is kept moist with damp surgical gauze.

Either a single layer skin flap – all four layers, skin, subcutis, muscle and periosteum are incised in a single cut, or a double layer skin flap can be performed.

A double layer skin flap may:

- reduce the chance of infection because the incisions are at different locations and layers, and
- allow better healing so it is often used for re-implantations and when encountering postauricular scar formation.

### Double layer skin flap (see Figure 27)

The four different tissue layers skin, subcutis, muscle, and periosteum are incised with two different incisions. First, the skin, subcutis and muscle are raised and retracted. Second, the periosteum is incised, the periosteum is freed from the surface of the bone and then retracted in another location.

Various methods may be used when incising the periosteum. Care should be taken to avoid incision over the implant later on.

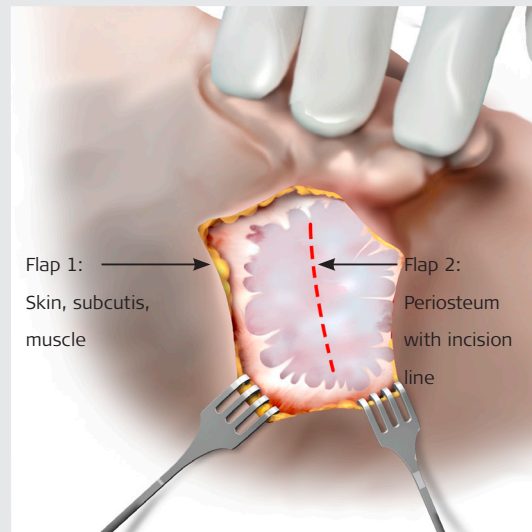


Figure 27 Double layer skin flap – right ear

## STEP 4-B: Skin Flap Thickness

In order to achieve good magnetic hold and optimal signal transmission, the skin flap or the muscle may need to be thinned out so it does not exceed 6 mm.

Evaluate the portion of the flap over the magnet and receiving coil with the Skin Flap Gauge 6, as shown in Figure 28. If the flap does not fit in the gauge loosely, carefully thin the flap until it does. It is important to avoid over-thinning of the flap, which may result in wound complications. Care must be taken to avoid exposing hair follicles.

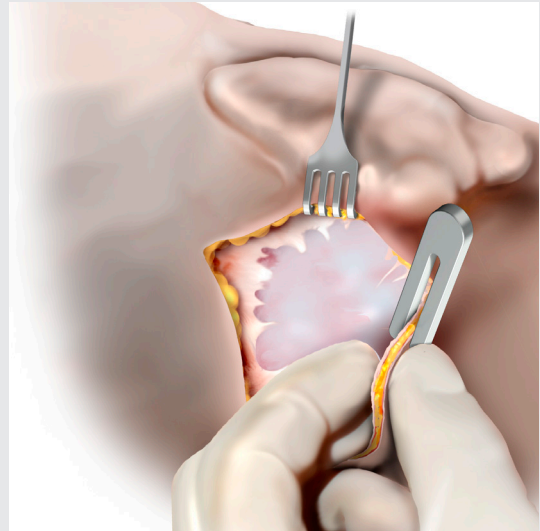


Figure 28 Using the Skin Flap Gauge 6 – right ear

## STEP 5: Check Position of Implant and Electrode Lead

### CAUTION

Retractors may distort the actual position of the implant in relation to the pinna as the ear is retracted.

The Mi1200 Implant Template should be placed on the skull in order to visually check its proper position. The bony ear canal should be identified and re-marking on the skull should be done if necessary (see Figure 29).

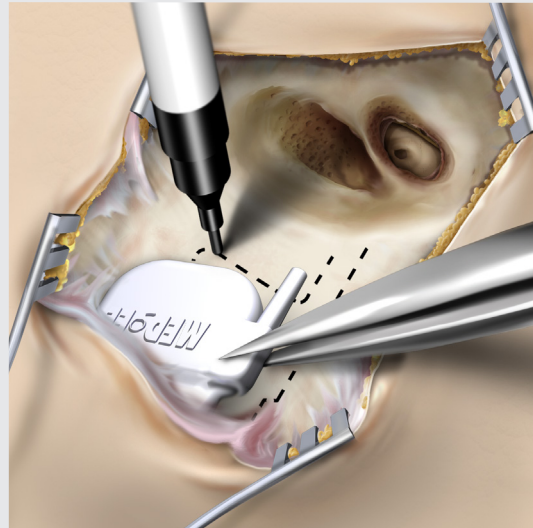


Figure 29 Marking the implant position with the Implant Template – right ear

## STEP 6: Drill Mastoidectomy and Posterior Tympanotomy

### CAUTION

Clear identification of the anatomical landmarks is required. When drilling, care should be taken to avoid exposing the dura inadvertently. If the dura is exposed as a landmark, exposure shall be kept to an absolute minimum. Inadequate large exposure or injury to the dura may reduce the barrier to future infection and may increase the potential risk for future meningitis. For example, neuro-radiological follow-up in cases of fractures of the anterior skull base have shown that foudroyantly progressing meningitis may occur, even years later. Similar mechanisms may also exist in respect of ear and mastoid surgery.

Facial nerve monitoring is recommended; when carried out, neuromuscular blockade should be avoided.

A standard cortical mastoidectomy is performed with a cutting burr, while ensuring good irrigation. A cortical overhang should be left, both superiorly and posteriorly; it can later serve as a natural support for the electrode lead as it is looped in the mastoid cavity.

The fossa incudis should be located, and the tip of the short process of the incus is identified to ensure the proper orientation of the posterior tympanotomy. This important part of the operation should be practiced many times on human cadaver temporal bones before live surgery is performed. A triangular opening is made between the mastoid and the facial nerve, which is referred to as the facial recess. The posterior limit is the vertical portion of the facial nerve, the anterior limits are the annulus and chorda tympani, and the upper aspect is a bony buttress at the level of the fossa incudis. Start drilling immediately below the fossa incudis, using a 3 mm diamond burr centered on the tip of the short process. Use high magnification and copious irrigation. Extreme care should be taken in drilling the posterior tympanotomy and the surgeon should be aware of any possible anatomical variants of the facial nerve.

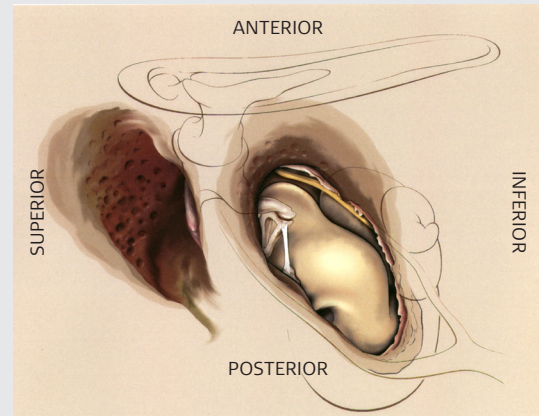


Figure 30 Anterior and posterior tympanotomy – right ear

The following should be visible after the posterior tympanotomy: the long process of the incus, the incudostapedial joint, the stapes pyramid and stapedius tendon, the promontory and the round window niche (see Figure 30 and Figure 31).

When the Fixation Clip will be used to stabilize the electrode lead inside the middle ear cavity care should be taken that the bony bridge (see Figure 32) is created accordingly to the dimensions of the Fixation Clip. The recommended size of the bony bridge is 2mm.

#### EAS

- It is recommended to create a larger posterior tympanotomy (as compared to that of a standard cochlear implantation) beside the anterior tympanotomy in order to provide a better view as well as more space to manoeuvre the electrode array.
- Elevate a mucosal flap to avoid mucosal bleeding when opening the cochlea.

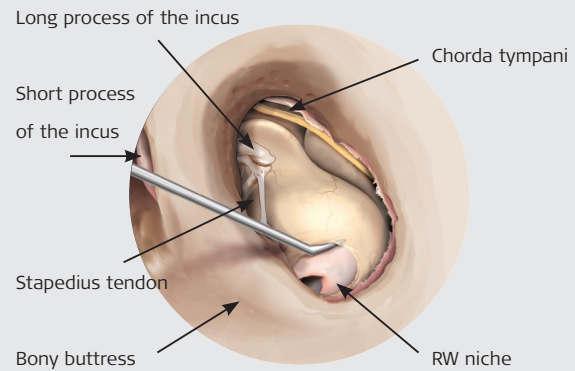


Figure 31 Posterior tympanotomy microscopic view – right ear

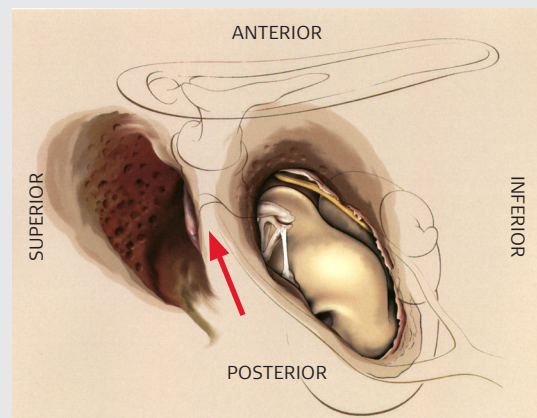


Figure 32 Bony bridge prepared for the Fixation Clip – right ear

## STEP 7: Drill Stimulator Bed and Electrode Channel

### CAUTION

- The implant must be immobilized in a flat stimulator bed drilled in the temporal bone. The electrode lead should be placed in a ramp-like bony channel without sharp edges to protect it against postoperative movement and excessive mechanical impact.
- The anterior stimulator edge should not be recessed to a depth more than 2 mm.
- All sharp edges of bone must be removed in order to avoid possible damage to the electrode lead. Drilling should be completed before the cochlea is opened to prevent any bone dust from entering.
- Protect the middle ear cavity from bone dust contamination by closing it with medical gauze.

The implant must be immobilized in a flat stimulator bed drilled in the temporal bone. In adults, it may not be necessary to expose the dura, but in small children with a thin skull, drilling to the dura may sometimes be required in order to ensure that the stimulator is well recessed in its bed. If drilling down to the dura is necessary a bony island should remain. Ideally, the stimulator is recessed approximately 2 mm.

Once again the Mi1200 Implant Template can be used to mark the flatness on the skull and the correct position for the implant bed (see Figure 33).

For protection and placement of the electrode lead, a smooth channel has to be drilled in the bone leading to the mastoid. Make sure that the channel is deep and wide enough to comfortably accommodate the electrode lead.

If, for example, the implant is fixed with sutures, a diamond burr should be used to drill the holes so that the implant can be immobilised later. The suture holes should be drilled such that the sutures do not cross the electrode, but rather only cross the silicone over-mold (see Figure 34).

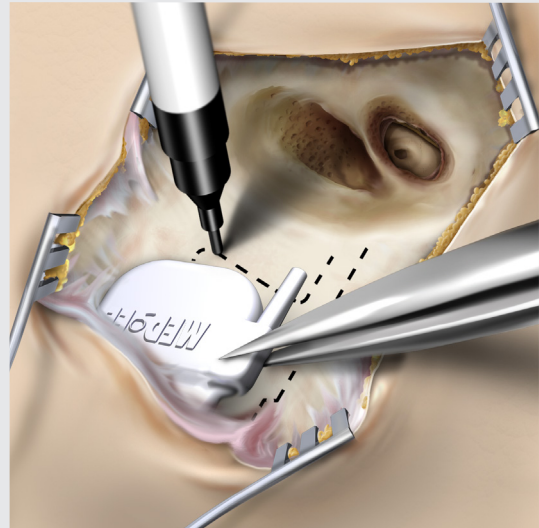


Figure 33 Marking the implant position with the Implant Template – right ear

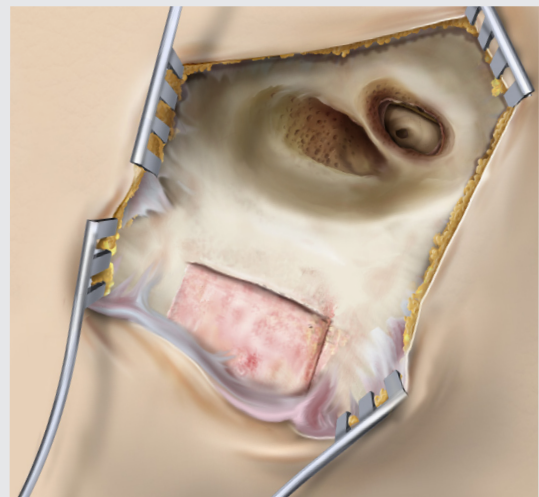


Figure 34 Flattening of the stimulator area – right ear

## STEP 8 – VARIANT 1: Preparation for a Round Window opening

### CAUTION

- Always use a slow turning diamond drill to avoid acoustic trauma when drilling the round window (RW) niche (approx. 1000rpm).
- Try to keep the RW membrane intact until the insertion of the electrode.

A clear view of the RW membrane is fundamental for the successful performance of a round window opening. Therefore, the posterior tympanotomy is usually slightly bigger drilled than a standard posterior tympanotomy to get a clear view onto the RW niche.

Before starting the preparation of the RW niche, a mucosal fold should be removed from the promontory. This prevents mucosal bleeding and provides better feedback from the tip of the drill (see Figure 35).

To facilitate the electrode insertion a portion of the anterior-inferior bony RW margin as well as the superior overhang of the RW niche needs to be drilled away. This increases the accessibility of the RW and prevents the electrode from being directed towards the modiolus. One potential risk associated with drilling the RW margin relates to its close proximity to the opening of the cochlear aqueduct. Care should be taken to avoid this inner ear structure.

Advantages of a RW opening:

- The amount of drilling is significantly reduced compared to a cochleostomy and no endosteal preparations in the direct vicinity of the basilar membrane are needed.
- The round window always leads into the correct scala for an electrode insertion – the scala tympani.

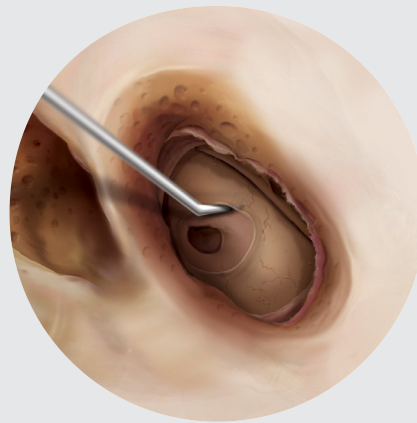


Figure 35 Elevating a mucosal flap – right ear



To enter the middle portion of the scala tympani and to get visualisation of the RW membrane, the posterior-superior lip of the round window niche and the inferior margin of the round window should be drilled away. By doing this, the round window will be exposed for best insertion of the electrode array (see Figure 36).

The RW niche is drilled and exposure should be extensive enough to comfortably fit the electrode. An appropriate RW opening in relation to size, is dependent upon the type of electrode array chosen. Please refer to STEP 9, "Select Appropriate Electrode Variant".

#### EAS

- Begin drilling near the cochlea use a slow turning diamond drill to avoid acoustic trauma.
- To enter the middle portion of the scala tympani and to get visualisation of the round window membrane, the posterior-superior lip of the round window niche and the inferior margin of the round window should be drilled away to expose the round window membrane at least 0.8mm.
- Fill the electrode insertion site with corticosteroid.
- Protect the middle ear cavity from bone dust contamination by closing it with medical gauze.

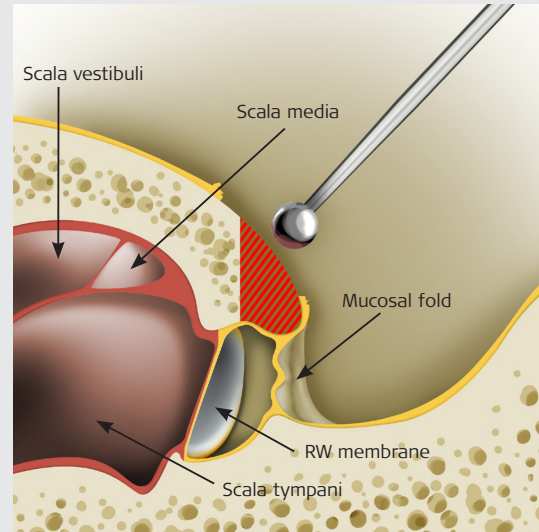


Figure 36 RW niche anatomy



## STEP 8 – VARIANT 2: Preparation for a Cochleostomy

### CAUTION

- For drilling the cochleostomy, always use a slowly turning diamond drill to avoid acoustic trauma (approx. 1000rpm).
- Try to keep the endosteum intact until the insertion of the electrode.

Before preparing to drill the cochleostomy, the mucosal fold should be removed over the promontory. This prevents mucosal bleeding and provides better feedback from the tip of the drill (see Figure 37).

The round window niche is identified and the cochleostomy is made inferior and slightly anterior to it. Many surgeons have a preferred technique to locate the best promontory point to begin drilling the cochleostomy. One recommendation is to use the width of the stapes as a measuring tool. The cochleostomy is made inferior to the stapedia tendon at a distance twice the width of the stapes and inferior and slightly anterior to the round window.

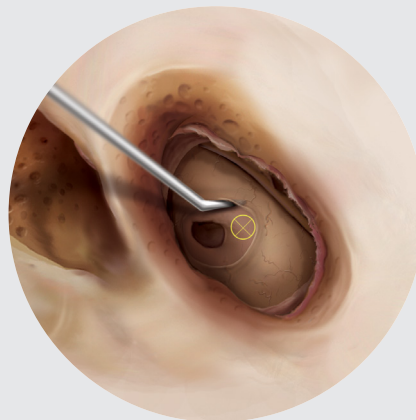


Figure 37 Removal of a mucosal fold & marking of cochleostomy – right ear

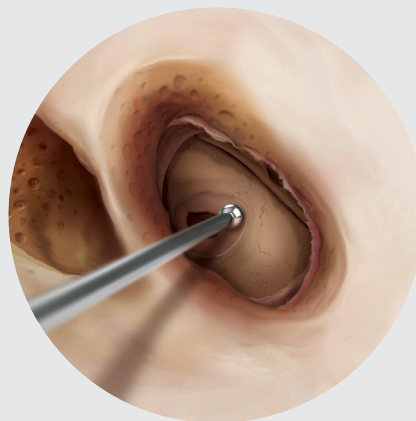

Figure 38 Drilling the cochleostomy inferior and slightly anterior to the round window – right ear

The cochleostomy is drilled and the exposure of the endosteum should be big enough to comfortably fit the electrode. An appropriate cochleostomy size is dependent upon the type of electrode array chosen. Please refer to STEP 9, "Select Appropriate Electrode Variant".

The bony lip of the cochleostomy is slightly smoothed with a small diamond drill bit.

#### EAS

- Begin drilling near the cochlea use a slowly turning diamond drill to avoid acoustic trauma.
- The cochleostomy should be drilled inferior and slightly anterior to the round window annulus to achieve a scala tympani insertion and to avoid damage to the osseous spiral lamina. The endosteum should be exposed to approximately 0.8 mm.
- Fill the electrode insertion site with corticosteroid.
- Protect the middle ear cavity from bone dust contamination by closing it with medical gauze.


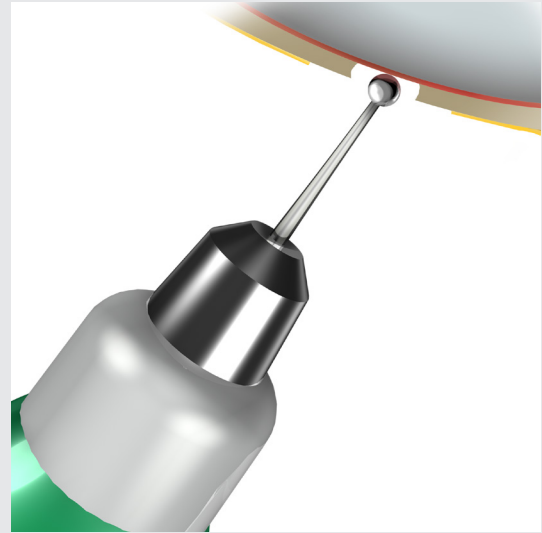


Figure 39 Drilling the cochleostomy and leaving the endosteum intact when drilling (upper picture), smoothing the edges of the cochleostomy (lower picture)

## STEP 9: Select Appropriate Electrode Variant \*

Complete Cochlear Coverage (CCC) means stimulating the cochlea from the base to the apical region in order to stimulate a maximum number of nerve fibres. Stimulation of the entire frequency range with a deeply inserted, long array provides the implant user with the best possible outcomes in speech performance measures and in sound quality.

MED-EL Cochlear Implants are available with several different electrode options. For hearing preservation with especially atraumatic electrode arrays, or for even the most difficult cases of cochlear ossification, obstructions or malformations (see Figure 40).

### Reduced Cochlear Duct Length or Malformations

Depending on the cochlear duct length or the malformation of the cochlea, a FORM24, FORM19, FLEX24, FLEX20, Medium or Compressed Electrode Array may be appropriate for optimal cochlear coverage and stimulation.

### Cochlear Ossifications

The surgeon must be prepared for unexpected findings during surgery. Depending on the degree of ossification, different surgical approaches and Electrode Arrays can be used.

### Partial Ossification

If only the inferior section of the basal coil is ossified, drilling along the basal turn can often reveal an open lumen in the further course of the scala tympani. In such cases, a FLEXSOFT, FLEX28 or Standard Electrode Array can be inserted.

If the ossification is also in the ascending section of the basal turn, and a drill-through cannot be achieved, there are various options:

- The cochleostomy can be widened in a superior direction to reach the scala vestibuli. If this scala is patent, a FLEXSOFT, FLEX28 or Standard Electrode Array can be inserted.
- The bridge, the incus and the crura of the stapes can be removed and a second cochleostomy can be drilled. An implant with a Split Electrode Array can be used, inserting one electrode array into the lower cochleostomy and the other into the upper cochleostomy.
- The Compressed Electrode Array can be inserted into the tunnel which has been drilled into the lower basal coil.

### Complete Ossification

In cases of complete ossification, the Split Electrode Array can be used. Two tunnels are drilled, one in the lower and one in the upper basal turn. The shorter 5-channel electrode array is inserted into the upper basal coil and the longer 7-channel electrode array into the lower basal coil.

### Insertion Test Tools

Evaluation of possible electrode insertion length for the individual patient should be done prior to the surgery. This can be performed by a standard X-ray or a CT scan.

With the help of the Insertion Test Tool, the Insertion Electrode (IE), the surgeon can establish whether the cochlear lumen is obstructed or if it is freely accessible up to different insertion depths depending upon the considered electrode variant planned for the implantation.

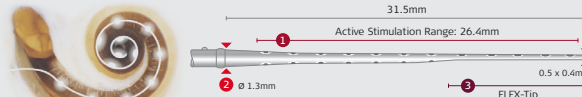
The Insertion Electrode variants shall not be used in patients where residual hearing shall be preserved.

\* Implant variants availability is subject to regulatory approval

**FLEXSOFT**

A 31.5mm electrode array featuring FLEX tip technology for increased mechanical flexibility and enabling CCC.

Order number: 31091

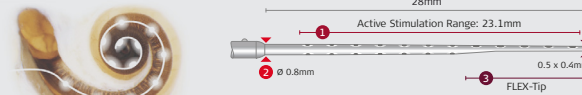


- 1 19 platinum electrode contacts  
Optimal spacing over a 26.4mm stimulation range
- 2 Diameter at basal end: 1.3mm
- 3 FLEX-Tip for minimal insertion trauma  
Dimensions at apical end: 0.5 x 0.4mm

**FLEX28**

A 28mm electrode array suitable for 96% of all normal cochlear duct lengths featuring FLEX tip technology. Optimised for insertion into the apical region (CCC).

Order number: 31093

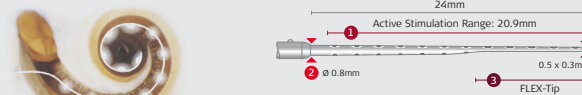


- 1 19 platinum electrode contacts  
Optimal spacing over a 23.1mm stimulation range
- 2 Diameter at basal end: 0.8mm
- 3 FLEX-Tip for minimal insertion trauma  
Dimensions at apical end: 0.5 x 0.4mm

**FLEX24**

A 24mm electrode array featuring FLEX tip technology and designed for combined Electric Acoustic Stimulation (EAS) with insertion less than 1.5 turns.

Order number: 31089




- 1 19 platinum electrode contacts  
Optimal spacing over a 20.9mm stimulation range
- 2 Diameter at basal end: 0.8mm
- 3 FLEX-Tip for minimal insertion trauma  
Dimensions at apical end: 0.5 x 0.3mm

**FLEX20**

A 20mm electrode array featuring FLEX-Tip technology and designed to be used in cases of partial deafness or for other specific needs or surgical preferences.

Order number: 31113

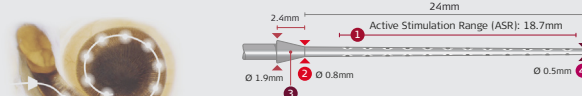


- 1 19 platinum electrode contacts  
Optimal spacing over a 15.4mm stimulation range
- 2 Diameter at basal end: 0.8mm
- 3 FLEX-Tip for minimal insertion trauma  
Dimensions at apical end: 0.5 x 0.3mm

**FORM24™**

A 24mm electrode array featuring CSF SEAL designed for open (no obliteration or ossification) or malformed cochleae, especially Type II malformations. Also for cases where CSF leakage is expected.

Order number: 31100

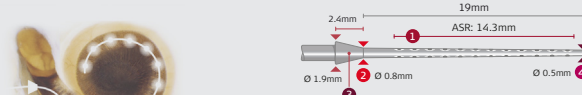


- 1 24 platinum electrode contacts  
Optimal spacing over a 18.7mm stimulation range
- 2 Diameter at basal end: 0.8mm
- 3 SEAL
- 4 Diameter at apical end: 0.5mm

**FORM19™**

A 19mm electrode array featuring CSF SEAL designed to be used in cochleae with malformation, especially Type I and Type III, obliteration, or ossification. Also for cases where CSF leakage is expected.

Order number: 31098

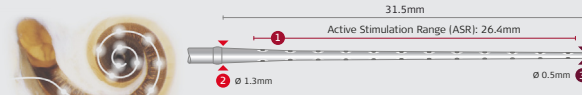


- 1 24 platinum electrode contacts  
Optimal spacing over a 14.3mm stimulation range
- 2 Diameter at basal end: 0.8mm
- 3 SEAL
- 4 Diameter at apical end: 0.5mm

**Standard**

A 31.5mm electrode array designed for long cochlear duct lengths.

Order number: 31084

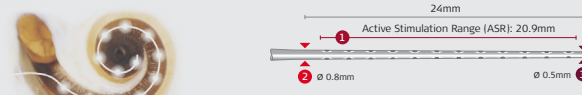


- 1 24 platinum electrode contacts  
Optimal spacing over a 26.4mm stimulation range
- 2 Diameter at basal end: 1.3mm
- 3 Diameter at apical end: 0.5mm

**Medium**

A 24mm electrode array designed for cases where deep insertion is not desired or is not possible due to anatomic restrictions.

Order number: 31087




- 1 24 platinum electrode contacts  
Optimal spacing over a 20.9mm stimulation range
- 2 Diameter at basal end: 0.8mm
- 3 Diameter at apical end: 0.5mm

**Compressed**

A 15mm electrode array designed for partial ossification or malformation of the cochlea.

Order number: 31097



- 1 24 platinum electrode contacts  
Optimal spacing over a 12.1mm stimulation range
- 2 Diameter at basal end: 0.7mm
- 3 Diameter at apical end: 0.5mm

Figure 40 MED-EL electrodes

## STEP 10: Immobilize the Implant

### CAUTION

- If monopolar diathermy has been used, it must now be disconnected. High current levels may cause damage to the implant. If bipolar cautery must be used, the tips of the cautery should be kept at least 3 cm away from the implant.
- Additional immobilisation of the implant needs to be performed.
- If sutures are chosen for immobilisation of the implant do not place the sutures directly over the electrode lead.

Additional immobilisation of the implant needs to be performed (e.g. with sutures). It should be conducted in such a way that there will be no postoperative movement. Continuous movement may result in mechanical fatigue and subsequent premature failure of electrical connections.

When the implant is immobilised with sutures, the holes drilled in STEP 7 should be used to secure the implant in its bed and the electrode should be placed into the drilled channel leading into the mastoid. Make sure the electrode channel is deep enough to prevent the tie-down from exerting pressure and damaging the electrode. MED-EL recommends the use of the following techniques (details in Figure 41, Figure 42).

In the event that the placement of the implant led to the protrusion of the reinforced part of the electrode into the mastoidectomy the following measures should be undertaken:

- Gently pre-shape the reinforced part of the electrode lead; without surgical instruments, using your hands only.
- Try to coil the rest of the electrode lead into the mastoidectomy, in such a way that additional pressure is not placed on the outer ear canal or the periosteum closing the mastoid cavity.

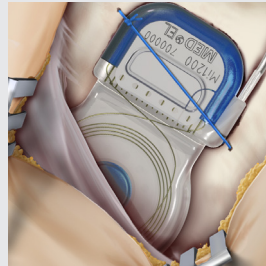


Figure 41 Implant immobilized with a single stitch – right ear

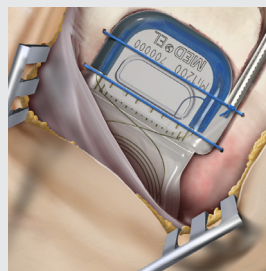


Figure 42 Implant immobilized with double stitches – right ear

## STEP 11: Opening the Cochlea

Before inserting the electrode array into the cochlea, either the RW membrane for a RW insertion or the endosteum for a cochleostomy insertion, needs to be incised.

Either a micro-lancette or a micro-hook can be used to open the cochlea (see Figure 43, Figure 44 and Figure 45).

### EAS

- Prior to opening the cochlea, clean the surgical field, change gloves, remove the gauze used to keep bone dust out of the middle ear cavity and administer a single dose of intravenous corticosteroids to protect the inner ear.
- Place a drop of corticosteroid on the round window membrane or endosteum to reduce fibrotic reaction and cover it with a drop of hyaluronic acid. This will keep the corticosteroid in place and protect it from bone dust.
- Using a micro-lancette or micro-hook, carefully incise the round window membrane in its inferior-anterior quadrant to approximately 0.8 mm.
- Using a micro-lancette or micro-hook, carefully incise the endosteum to approximately 0.8 mm.
- Avoid suctioning in the open region of the cochlea.

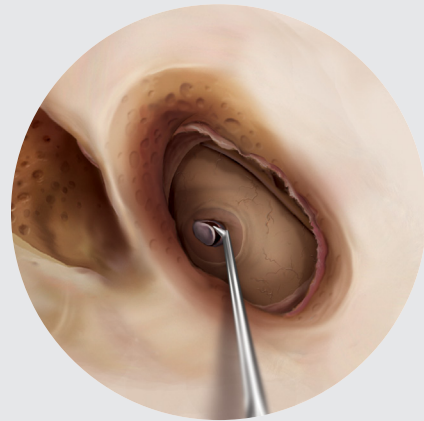

Figure 43 RW membrane incision with a 45° micro-hook

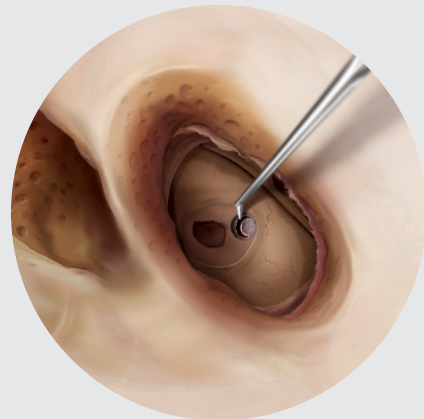

Figure 44 Endosteum incision with a 45° micro-hook

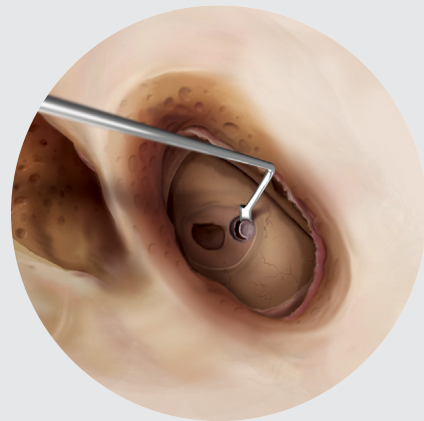


Figure 45 Endosteum incision with a micro-lancette

## STEP 12: Insert the Electrode Array

### CAUTION

- Only surgical tools approved by MED-EL should be used to insert the electrode array into the cochlea.
- Under no circumstances should any force be used during electrode insertion.
- Insertion of the electrode array into the cochlea will probably destroy remaining hearing that was present in that ear prior to surgery.

It is important for the electrode array to approach the anterior portion of the basal turn at an angle so that it slides along the lateral wall of the scala tympani. This procedure, known as tangential insertion, facilitates deep electrode insertion (see Figure 46).

The individual insertion angle for each case should be considered in order to reach a tangential electrode insertion (see Figure 47). Non-tangential insertion should be avoided.

Surgical tools approved by MED-EL should be used to insert the electrode array into the cochlea, please see section III. Surgical Tools. Either the Surgical Claw or the Micro Forceps Angled can be used to maneuver the electrode array. The type of Micro Forceps Angled used, to insert the electrode in a left or a right cochlea, depends on the preference of the surgeon. Use of lubrication or anti-inflammatory compounds during electrode insertion is up to the surgeon.

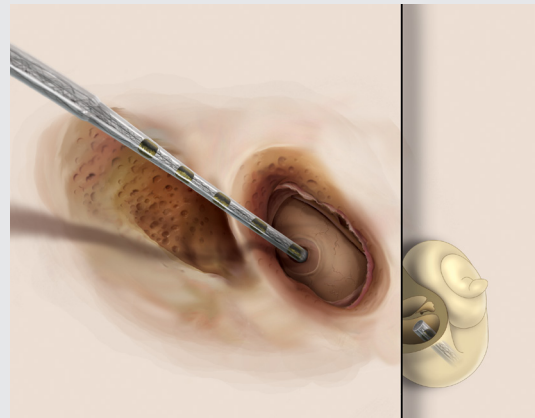


Figure 46 Direction of electrode insertion – right ear

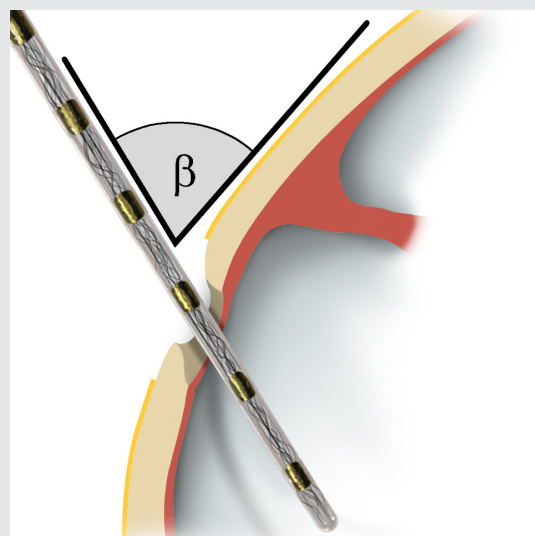


Figure 47 Insertion angle to reach a tangential electrode insertion



The electrode lead is held very carefully at the proximal thicker part, just above the marker ring. If using a FLEX-style electrode array, orient the single contacts along the apical portion of the array toward the modiolus of the cochlea during insertion so that the marker dot at the base of the array will point toward the modiolus after insertion. The tip of the electrode array is guided toward the cochlea opening. After the tip is gently maneuvered further into the cochlea, gripping of the electrode array between the contacts can be done (see Figure 48). During insertion it is essential that the electrode contacts are not mechanically damaged and that no excessive force should be used.

Please be aware that sealing of the cochlear opening with the marker ring should not be achieved with the Medium and Compressed Electrode Arrays.

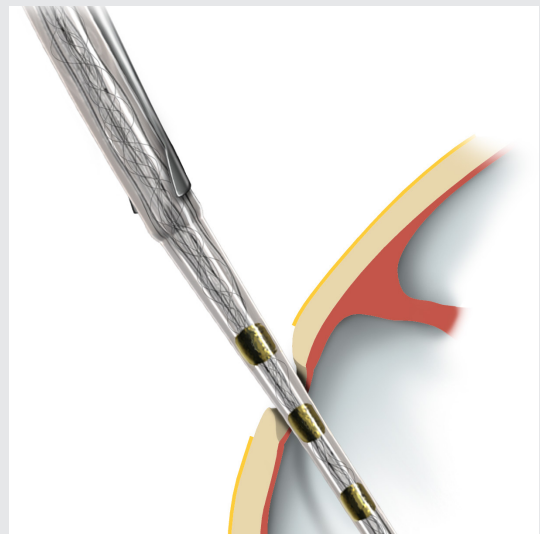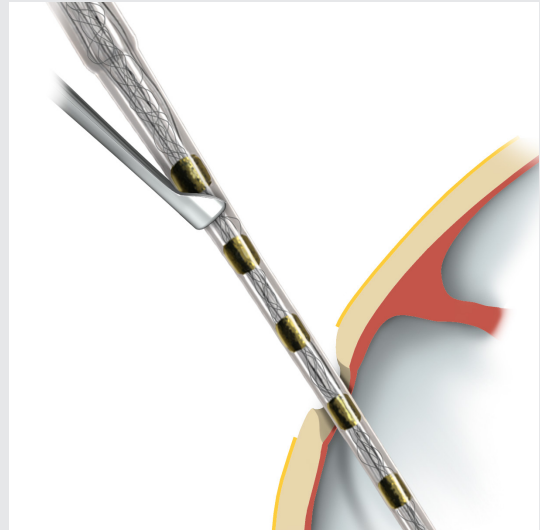


Figure 48 Detail of electrode insertion – manoeuvre the electrode array between the contacts & after the marker ring



If resistance is encountered before reaching the marker ring, the electrode array may buckle. In such cases, electrode insertion should be stopped. Excessive force should not be used, as it may result in intra-cochlear damage.

The following measures may be helpful in such situations:

- **Carefully rotate the electrode**  
Due to the unique oval design of the electrode array, the electrode can be slightly rotated to allow it to slide deeper into the cochlea.
- **Small movements close to the insertion site**  
Hold the electrode no more than 2 mm from the cochleostomy or round window opening. Gently insert the electrode with one stroke, release it and grasp it again 2 mm from the insertion side. Repeat this procedure until complete insertion is achieved.
- **Slow the rate of insertion**  
Slow the speed that the electrode is introduced into the opening. Frequent pauses during insertion can allow the electrode to gently slide along the cochlear duct.
- **Use of lubricant**  
As known from soft surgical techniques, the use of a lubricant can help smoothing the electrode insertion.

#### EAS

- Immediately start the electrode insertion through the drop of corticosteroid and hyaluronic acid.
- General insertion direction is from superior-posterior to anterior-inferior with the knob indicating the direction of the apical electrodes facing towards the modiolus.

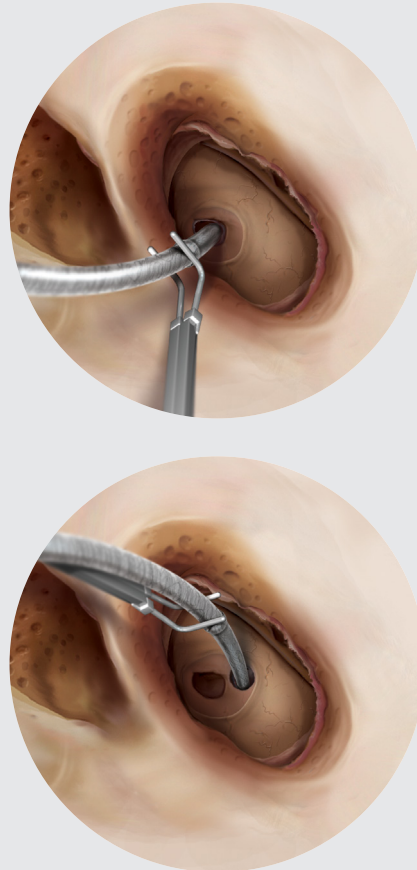


Figure 49 Full insertion of the electrode array – forceps positioned behind the marker ring – right ear

## STEP 13-A: Seal Cochlear Opening

### CAUTION

- To minimize the risk of postoperative infection additional sealing of the cochlear opening should be done for all MED-EL electrode arrays.
- Once the electrode array has been inserted into the cochlea, the electrode lead should be fixed so that no postoperative movement will occur.
- Please be aware that sealing of the cochlear opening with the marker ring should not be achieved with the Medium and Compressed Electrode Arrays.

When the electrode array is fully inserted, the marker ring will aid sealing the cochlear opening during surgery and providing an additional point of fixation (see Figure 50). This sealing will only take place with the FORM24, FORM19, FLEXSOFT, FLEX28, FLEX24, FLEX20 and Standard Electrode Array fully inserted.

For all MED-EL Electrode Arrays, small pieces of temporalis fascia placed around the electrode array at the entrance to the cochlea shall be used to secure the electrode array and to seal the opening. Rinse the small pieces with saline solution to prevent contamination of the electrode and to increase flexibility.

### EAS

- To seal the cochlea, use a small fascial graft. To prevent contamination of the electrode and to increase flexibility, rinse the fascial graft with saline solution.

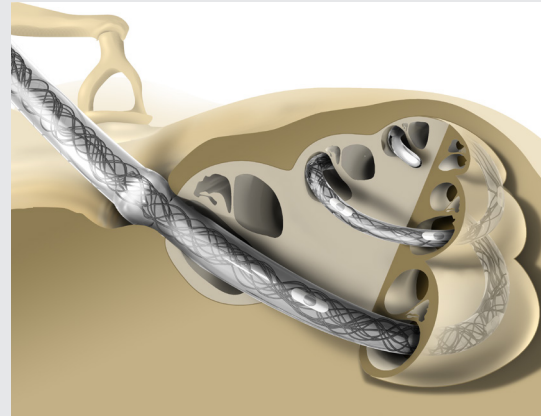


Figure 50 The marker ring of the Standard Electrode Array can seal the cochlear opening, aiding in its fixation – right ear

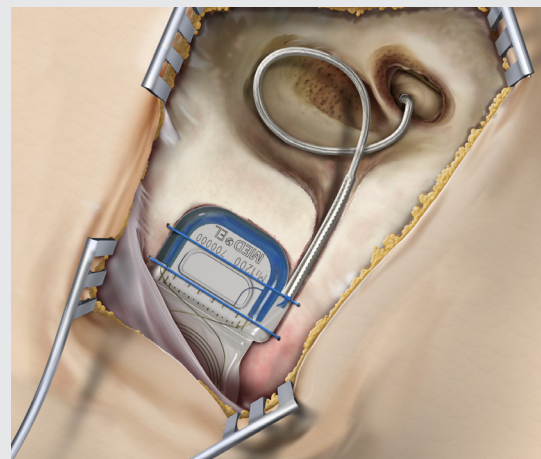


Figure 51 The electrode lead should be loosely placed under the cortical overhang – right ear

## STEP 13-B: Secure Electrode Lead

If you choose to secure the electrode lead in the posterior tympanotomy, fibrin glue or bone paté can be used. MED-EL offers a Fixation Clip to secure the electrode lead to the bony bridge (incus bridge).

### Securing the electrode lead with the Fixation Clip\*

Order number: 09917

#### CAUTION

- The Fixation Clip shall not be used in the case that the bony bridge is not suitable for placing the Fixation Clip.
- The recommended size of the bony bridge is 2 mm.
- Accidental bending of the Fixation Clip during removal from its packaging must be avoided in order to prevent functional damage.
- Care should be taken that during the fixation of the bone fixation clip the Incudostapedial joint is not harmed and the movements of the ossicles are not inhibited.
- Care should be taken not to squeeze or damage the electrode.

The Fixation Clip shall be used exclusively with MED-EL electrodes that have a diameter of 1.3 mm at the distal part of the electrode lead (see Figure 53).

The openings are not of the same size. The larger opening of the Fixation Clip is the bone fixation clip and the smaller opening of the Fixation Clip is the electrode fixation clip (see Figure 54).



Figure 52 Fixation Clip Ms010103

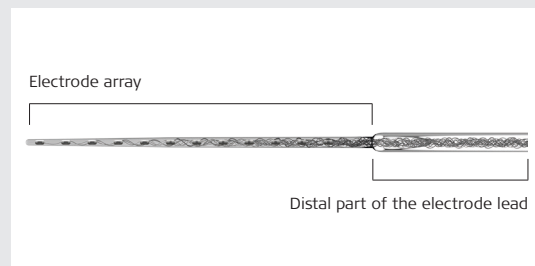


Figure 53 Distal part of the electrode lead

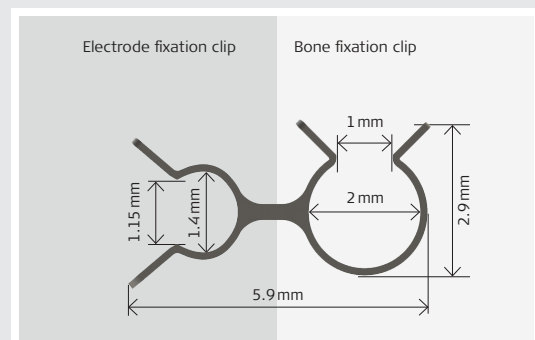


Figure 54 Dimensions of the Fixation Clip

\* Fixation Clip development was in close collaboration with Prof. Joachim Müller, Klinik und Poliklinik für Hals-, Nasen- und Ohrenheilkunde München Großhadern, Germany

First the larger clip (bone fixation clip) shall be placed on the bony bridge (see Figure 55).

Next, the bone fixation clip shall be properly crimped to the bony bridge (see Figure 56). For crimping the Fixation Clip a micro forceps should be used (e.g. Hartmann Alligator Forceps, 8 mm).

After fixing the bone fixation clip, the electrode fixation clip shall be closed over the electrode lead so that both ends of the electrode fixation clip come together and the clip is completely closed (see Figure 57).

The electrode lead is longer than required in order to accommodate anatomical variants and to compensate for skull growth in children.

The electrode lead is looped in the mastoid cavity well below the surface of the bone, using the cortical overhang to hold it in place to avoid postoperative movements due to contractions of the temporalis muscle (see Figure 58).

Additional immobilisation of the electrode lead inside the electrode channel could be done, e.g. with bone paté or bone wax.

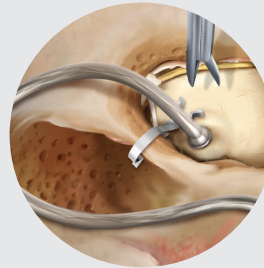


Figure 55 Placement of the Fixation Clip on the bony bridge

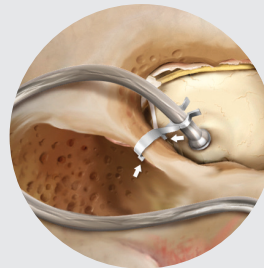


Figure 56 Bone fixation clip crimped on the bony bridge

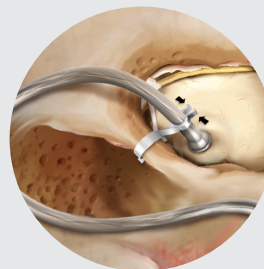


Figure 57 Electrode fixation clip closed over the electrode

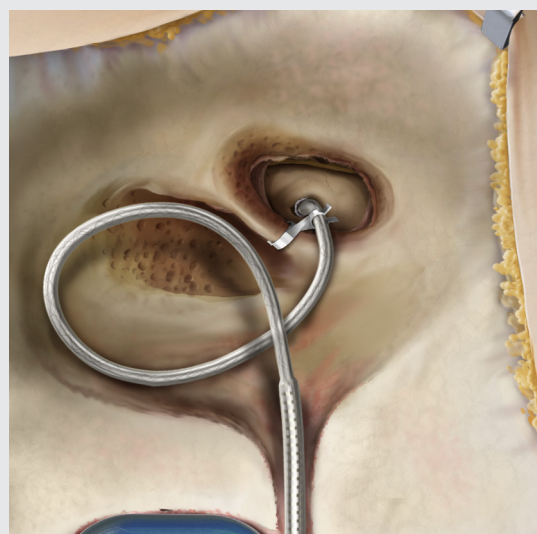


Figure 58 The electrode lead should be loosely placed under the cortical overhang – right ear

## STEP 14: Intra-operative Recordings

At this stage intra-operative recordings like Impedance Field Telemetry (IFT), Electrically Evoked Stapedius Reflex Threshold (ESRT), Electrically Evoked Brainstem Response (EABR) or Auditory Nerve Response Telemetry (ART) can be performed.

Intra-operative measurements are performed with the appropriate MED-EL application software and the MED-EL hardware interface system. For details please refer to the applicable Software User Manual. It is not possible to sterilise any component of the MED-EL hardware interface system. When used in a sterile environment, the coil and cable should be covered with sterile material (i.e. "sterile sleeve"). The appropriate coil should be used during intra-operative recordings.

Since the coil should not be placed directly on the implant, either sterile gauze drenched in saline solution or the skin flap should be placed between the coil and the implant. Moistening the underside of the skin flap with sterile saline or pooling saline over the ground electrode of the implant prior to performing intra-operative recordings may improve readings.

### IFT (Impedance Field Telemetry)

After the implant is in place, a telemetry check allows:

- individual electrode impedance measurements
- verification of the absence of short and open circuits between electrodes
- determination of intra-cochlear voltage distribution

As with any telemetry system, intra-operative impedance testing may not provide an accurate representation of later electrode function. "High" values observed intra-operatively may be caused by air bubbles on the electrode contact surface. These generally dissipate within a few hours or days after surgery.

### ESRT (Electrical Stapedius Reflex Threshold)

If ESRT thresholds are measured, care should be taken that no muscle relaxant is used during the last half hour before performing the measurements.

Note that observation of the reflex is not possible in some implanted patients due to various physiological and anatomical reasons. In addition, observation of the reflex may not be possible due to anaesthesia. Therefore, absence of a reflex should not be taken as an indication of implant malfunction or lack of auditory response without other more direct evidence.

Intra-operatively, the presence of the reflex can be monitored either by direct observation of the ipsilateral tendon, through the microscope, or by impedance probe measurements in the contralateral ear. Direct observation is employed in most cases, as this is normally straightforward and does not require additional equipment. Probe measurements are usually restricted to research studies.

## EABR (Electrically Evoked Brainstem Response)

With the addition of the EABR task, it is possible to measure and record the response of the entire auditory pathway to stimulation from the implant. EABR recordings can be used to determine the best placement of an Auditory Brainstem Implant during surgery, and they can also provide interesting information on the function of the whole auditory pathway. The MED-EL application software EABR parameters can be adjusted to facilitate recording of early, middle and late electrical potentials. To obtain measurements with the EABR task, it is necessary to also use a separate neurodiagnostic computer with a trigger input, along with scalp recording electrodes.

## ART™ (Auditory Nerve Response Telemetry)

MED-EL offers implants that are capable of recording compound action potentials – small voltage changes that are created by the auditory nerve when it transmits a signal to the brainstem. The measurement is done a few microseconds after the end of a stimulation pulse. The recorded signal is called the Evoked Compound Action Potential (ECAP or EAP) of the auditory nerve. It has an amplitude of about 0.01 to 2 mV and takes place within roughly one millisecond after the stimulation pulse. Due to these very short, small response levels, special artifact reduction methods are used to enhance viewing of the nerve response.

## STEP 15: Close Wound

For additional immobilisation of the implant and the electrode lead, the periosteum should be separately sutured over the implant region and the mastoid cavity. Care should be taken not to damage the implant or the electrode.

The rest of the wound should be closed in layers with staples or absorbable subcutaneous sutures.

The area of the wound is covered with a compress and sterile gauze applying even pressure.

### EAS

- A course of steroids and antibiotics should be given postoperatively.

# Appendix

## MRI CAUTION

Evidence has been provided for this implant type to pose no known hazard in specified MRI environments (without surgical removal of the internal magnet) when adhering to the conditions and Safety Guidelines listed below. The implant has a specially designed magnet which allows safe MRI scanning with the magnet in place, and there is no need to remove the implant magnet regardless of the scanner field strength. The implant magnet can be surgically removed if needed to avoid imaging artifacts. The physician/MRI operator should always be informed that a patient is a cochlear implant user and that special safety guidelines have to be followed:

**MRI scanning is possible in consideration of the Safety Guidelines if the following conditions are fulfilled:**

- MRI scanners with static magnetic fields of 0.2 T, 1.0 T, 1.5 T or 3.0 T only. No other field strengths are allowed. When using other field strengths, injury to the patient and/or damage to the implant are possible.
- In case of additional implants, e.g. a hearing implant in the other ear: MRI safety guidelines for this additional implant need to be met as well.

### Safety Guidelines:

- Before patients enter any MRI room all external components of the implant system (audio processor and accessories) must be removed from the head. For field strengths of 1.0 T, 1.5 T and 3.0 T, a supportive head bandage must be placed over the implant. A supportive head bandage may be an elastic bandage wrapped tightly around the head at least three times (refer to Figure 59). The bandage shall fit tightly but should not cause pain. Performing an MRI without head bandage could result in pain in the implant area and in worst case can lead to migration of the implant and/or dislocation of the implant magnet.




Figure 59 Head bandage to support fixation of the implant.

- Head orientation: In case of 1.0 T, 1.5 T and 3.0 T MRI systems, straight head orientation is required. The patient should not incline his/her head to the side; otherwise torque is exerted onto the implant magnet which could cause pain. In case of 0.2 T scanners, no specific head orientation is required.
- For 0.2 T, 1.0 T and 1.5 T scans sequences in "Normal Operating Mode" shall be used only. For 3.0 T scans the SAR limit must not exceed 1.6 W/kg to avoid any potentially dangerous heating at the electrode contacts. For the same reason head transmit coils or multi-channel transmit coils must not be used in case of a 3.0 T MRI.
- During the scan patients might perceive auditory sensations such as clicking or beeping. Adequate counseling of the patient is advised prior to performing the MRI. The likelihood and intensity of auditory sensations can be reduced by selecting sequences with lower specific absorption rate (SAR) and slower gradient slew rates.
- The magnet can be removed by pushing on the top side of the magnet so that it comes out at the bottom side of the implant to reduce image artifacts. If the magnet is not removed, image artifacts are to be expected (refer to Figure 64 and Figure 65).



- The exchange of the magnets with the Non-Magnetic Spacer and vice versa has been tested for at least five repetitions.
- The above instructions should also be followed if areas of the body other than the head are to be examined (e.g. knee, etc.). When lower extremities are to be examined, it is recommended that the patient's legs are positioned in the scanner first.

If the conditions for MRI safety and the Safety Guidelines are not followed, injury to the patient and/or damage to the implant may result!

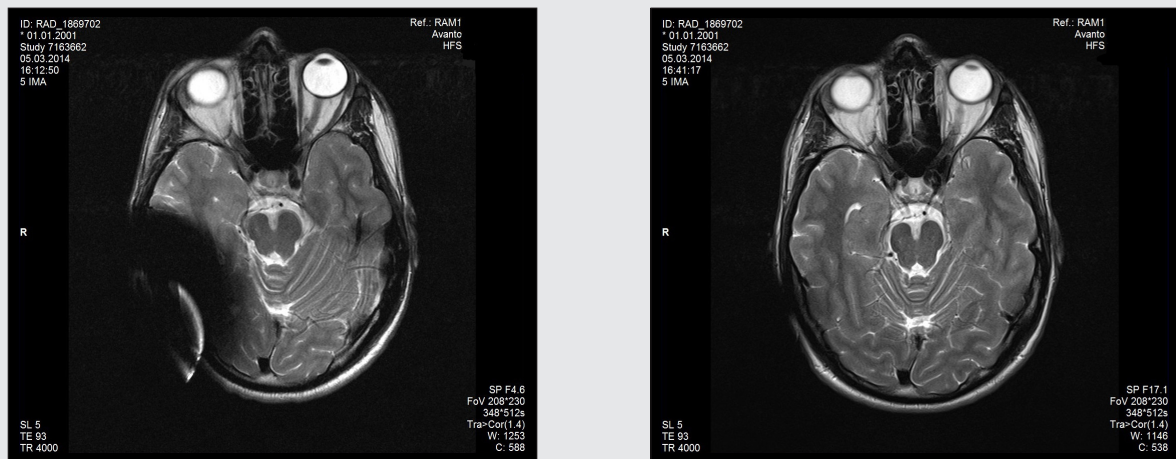


Figure 60 Image artifacts arising in a 1.5 T scanner. The left picture shows the artifacts obtained with the implant magnet in place whereas the right picture illustrates the image artifacts when the implant magnet is replaced with the Non-Magnetic Spacer.

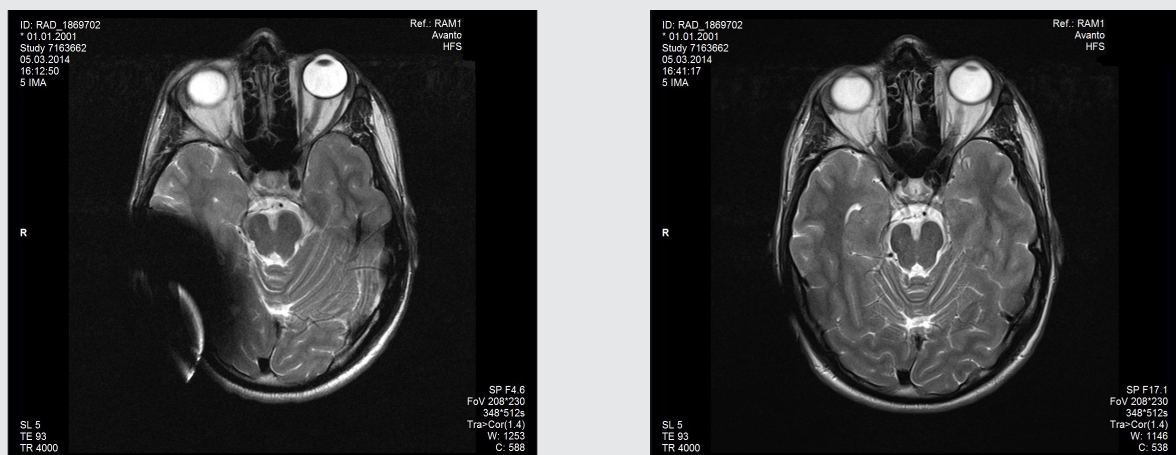


Figure 61 Image artifacts arising in a 3 T scanner. The left picture shows the artifacts obtained with the implant magnet in place whereas the right picture illustrates the image artifacts when the implant magnet is replaced with the Non-Magnetic Spacer.



## Magnet Removal Procedure

The following instruments are required for the Magnet Removal Procedure:

### Magnet Replacement Kit

Order number: 09693

Consisting of:

#### Non-Magnetic Spacer Ms010107

The Non-Magnetic Spacer (see Figure 62) is intended to be used as placeholder for the regular implant magnet of the Mi1200 Hearing Implant during MRI procedures, when a reduced image artifact is desirable.

#### Replacement Magnet Ms010108

The Replacement Magnet (see Figure 63) is intended to be used after an MRI, as replacement of the original implant magnet of the Mi1200 Hearing Implant and to restore full functionality of the Mi1200 Hearing Implant.

### Magnet Tool Kit

Order number: 09734

Consisting of:

#### Magnet Removal Tool Ms050206

#### Magnet Insertion Tool Ms050205

The Magnet Removal Tool (see Figure 64) is for removal of the MED-EL removable implant magnet and the Non-Magnetic Spacer.

The Magnet Insertion Tool (see Figure 65) is for insertion of the Non-Magnetic Spacer and the Replacement Magnet.

The instruments are made of surgical grade stainless steel. The devices are delivered non-sterile.



Figure 62  
Non-Magnetic Spacer



Figure 63  
Replacement Magnet

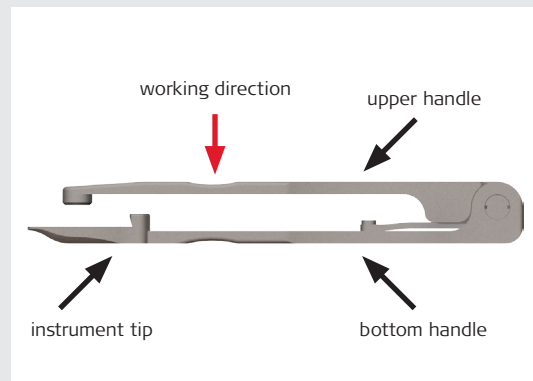


Figure 64 Magnet Removal Tool

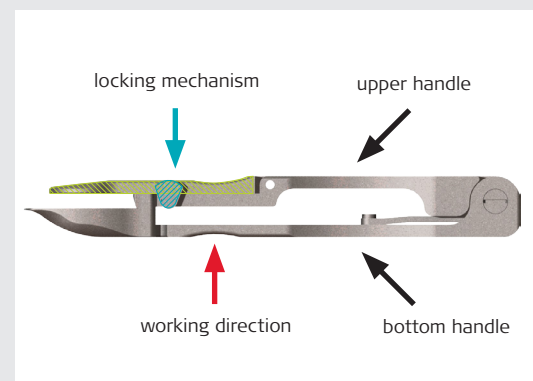


Figure 65 Magnet Insertion Tool

## Surgical Procedure

### STEP 1: Opening the skin flap

When opening the skin flap, keep an adequate distance between the incision and the coil. This will prevent damage to the implant under the skin. For marking the incision either the patient's audio processor coil or the MAX Coil S can be used. When used in a sterile environment, the Coil should be covered with sterile material (i.e. "sterile sleeve"). MED-EL recommends a distance of 5 to 15 mm from the coil and an opening angle between  $160^\circ$  and  $200^\circ$ . Carefully dissect the fibrous tissue to locate the coil part of the implant and expose the magnet. The wound should be opened in layers.

### STEP 2: Removing the Implant Magnet or Non-Magnetic Spacer

#### CAUTION

To avoid movement of the implant it is recommended to fix the stimulator by pressing it against the bone with one hand.

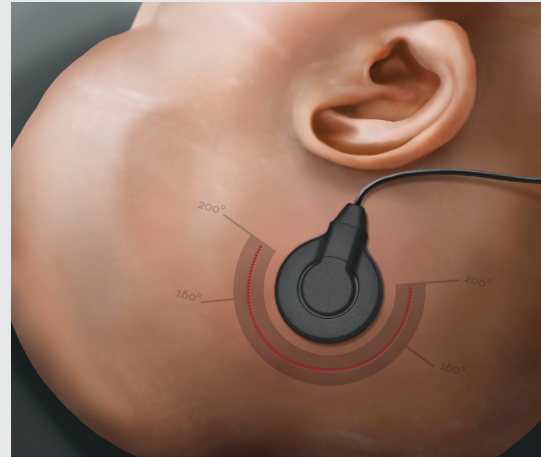


Figure 66 Showing recommended incision line with MAX Coil S in non-sterile environment

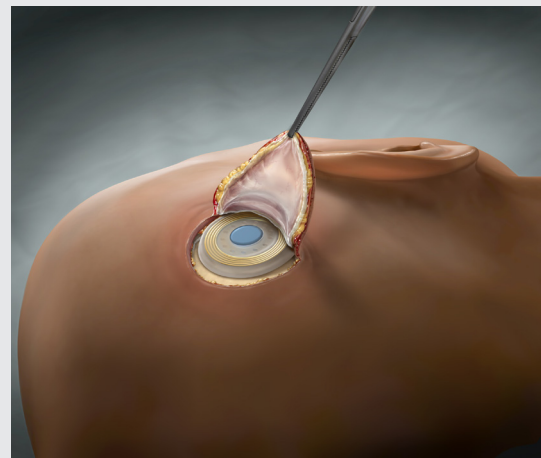


Figure 67 Implant coil with inserted magnet after opening the skin flap

1. Place the Magnet Removal Tool in front of the implant coil.
2. Lift the coil part of the implant by sliding the tip of the Magnet Removal Tool under the implant coil.
3. Centre the implant coil in the tip part of the Magnet Removal Tool.
4. Push the Implant Magnet or Non- Magnetic Spacer out of the implant coil by pressing together the two handles of the Magnet Removal Tool.
5. MED-EL recommends checking that the two handles of the Magnet Removal Tool are completely re-opened before pulling out the instrument.
6. Remove the Magnet Removal Tool by slowly pulling out the instrument from the implant coil.
7. After pulling out the instrument, the Implant Magnet or Non-Magnetic Spacer can be removed from the tip of the Magnet Removal Tool by lifting the upper handle. The removed Implant Magnet or Non-Magnetic Spacer can be disposed of.

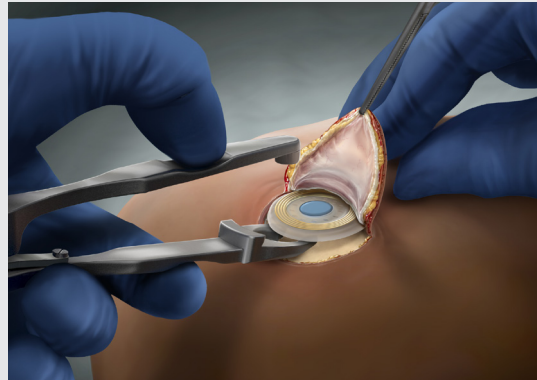


Figure 68 Lifting the implant coil with the Magnet Removal Tool


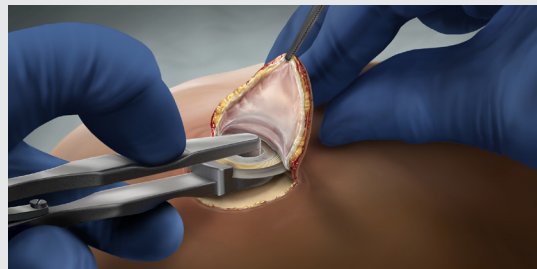


Figure 69 Centering the implant coil and pressing the two handles together for removing the magnet

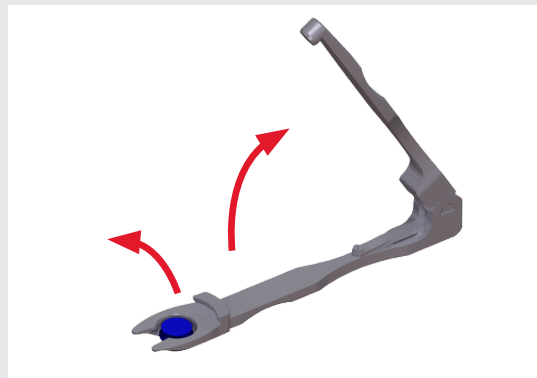


Figure 70 Opening the instrument and removing the magnet from the instrument tip

### STEP 3: Inserting the Non-Magnetic Spacer or Replacement Magnet

#### CAUTION

To avoid movement of the implant it is recommended to fix the stimulator by pressing it against the bone with one hand.

1. Open the upper handle of the Magnet Insertion Tool by unlocking the small locking mechanism and lifting the counter blade.
2. Place the Non-Magnetic Spacer or Replacement Magnet in the front part of the Magnet Insertion Tool. The Non-Magnetic Spacer or Replacement Magnet is correctly placed into the tip when the serial number labelling is not readable from the top.
3. Close the counter blade and lock the locking mechanism.
4. Place the Magnet Insertion Tool in front of the implant coil.
5. Lift the coil part of the implant by sliding the tip of the Magnet Insertion Tool under the implant coil.

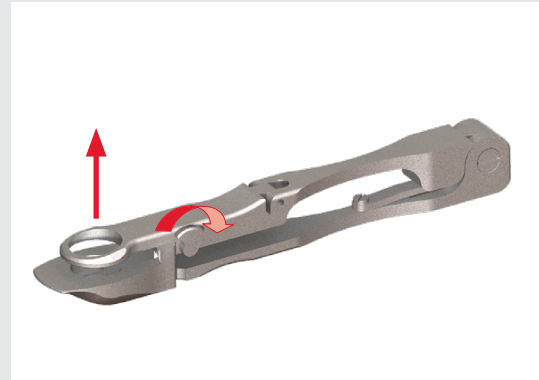


Figure 71 Unlocking the locking mechanism and lifting the upper handle

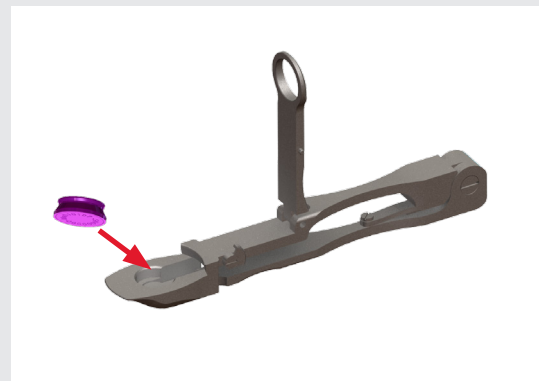


Figure 72 Placing the Non-Magnetic Spacer or the Replacement Magnet in the tip of the Magnet Insertion Tool

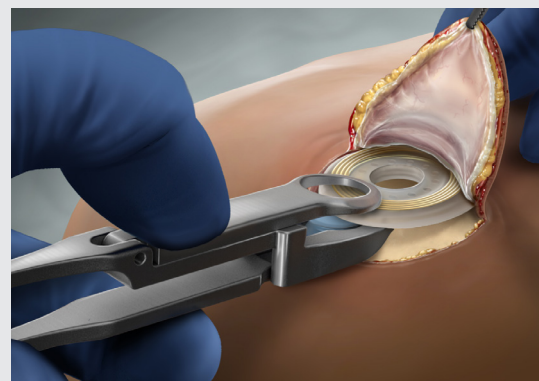


Figure 73 Lifting the implant coil with the Magnet Insertion Tool

6. Centre the implant coil in the tip part of the Magnet Insertion Tool so the Non-Magnetic Spacer or Replacement Magnet is completely visible through the hole in the implant coil.
7. For complete insertion of the Non- Magnetic Spacer or Replacement Magnet into the implant coil, insert the Non- Magnetic Spacer or Replacement Magnet into the implant coil by pressing the two handles of the instrument together until the two handles are touching.
8. Re-open the two handles of the Magnet Insertion Tool.
9. MED-EL recommends checking that the two blades of the Magnet Insertion Tool are completely re-opened before pulling out the instrument.
10. Remove the Magnet Insertion Tool by slowly pulling out the instrument from the implant coil.
11. Check the correct magnet position.

#### STEP 4: Close wound

Before closing the wound visually confirm that the blue Replacement Magnet (Ms010108) or the purple Non-Magnetic Spacer (Ms010107) was inserted as appropriate. When closing the wound, care should be taken not to damage the implant. The wound should be cleaned and closed in layers with staples or absorbable subcutaneous sutures. The area of the wound should then be covered with a compress and sterile gauze, and even pressure should be applied.

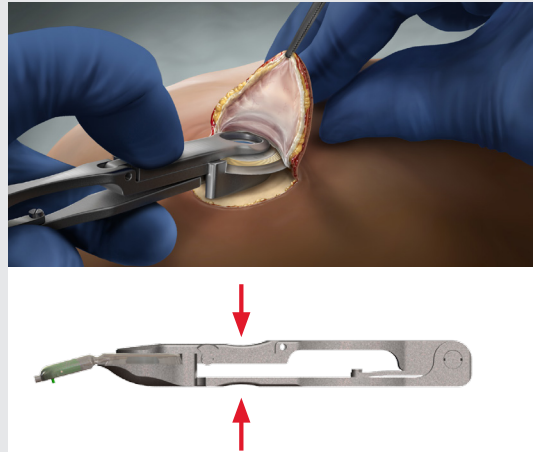


Figure 74 Centering the implant coil and pressing the two handles together for inserting the magnet

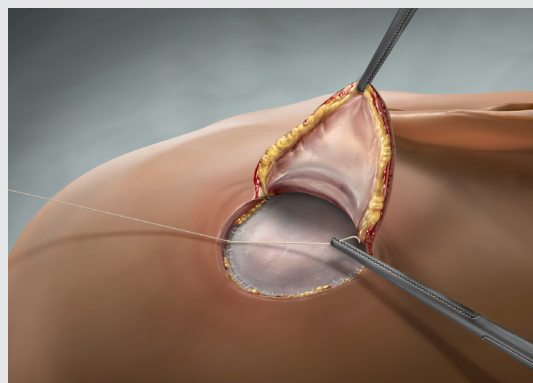


Figure 75 Suturing the wound

## X-rays

The SYNCHRONY Cochlear Implant can be identified by X-ray post surgery. Right is an example for the device.

## Explanting the Device

- The implant may become non-functional, either by accident or due to medical or technical reasons. In this case, it is strongly recommended to replace the device.
- If for any reason the device is not used anymore, it is strongly recommended to explant the device. If an explantation is not performed, functional checks of the implant on a regular basis are strongly recommended.
- If possible, the device should be removed without damaging or cutting it. Damage to the device during or after explantation may prevent or reduce the manufacturer's ability to determine the root cause of failure.
- Staff should follow common universal precautions and handle the explanted device as potentially contaminated biohazardous material.
- After explantation, the implant should be appropriately cleaned and disinfected. During cleaning, extraneous tissue should be removed, but only to such an extent that damage to the implant is not risked.
- An explanted device should be placed in a leak-proof, disinfected (or sterile) container filled with saline and returned to MED-EL Headquarters. The device should be accompanied by written information including the reason for explantation.

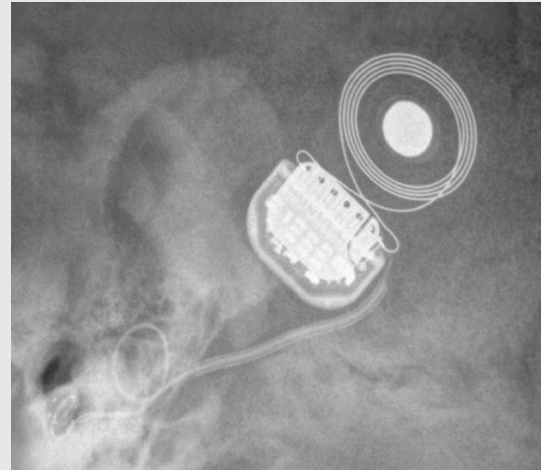


Figure 76 X-ray

## MED-EL Surgical Videos

MED-EL Surgical (SONATA, PULSAR)

Order number: MKT 20265

EAS Surgical Video

Order number: MKT 20542

Small Incision Surgical Video

Order number: MKT 21627

Frankfurt, Germany Live Surgery DVD\*

Order number: MKT 22987

MED-EL Advanced Surgical Techniques

3D BluRay English

Order Number: MKT 23518

For additional videos please visit the MED-EL Professional  
Webpage ([www.medel.com/professionals](http://www.medel.com/professionals))

\* Note that the featured surgery is performed in Germany and the techniques / variants used may differ from other markets.



## Hearing Preservation Surgical Technique

A special marked paragraph can be found in each Surgical Step showing details which are important for Hearing Preservation for an EAS surgery. A summary on the additional EAS related surgical steps can be found in Figure 77.

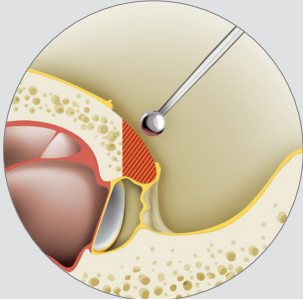
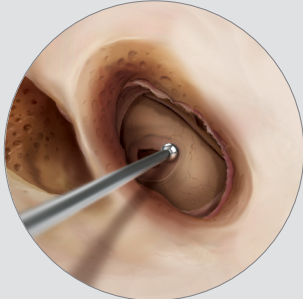
Round Window Insertion	Cochleostomy Insertion
Please ensure that corticosteroids (crystalline triamcinolone solution or dexamethasone), intravenous corticosteroids, and hyaluronic acid are all available for the surgery.	
Administer intravenous antibiotics from the Cephalosporin group and intravenous corticosteroids at least half an hour before the skin incision.	
It is recommended to create a larger posterior tympanotomy (as compared to that of a standard cochlear implantation) beside the anterior tympanotomy in order to provide a better view as well as more space to manoeuvre the electrode array.	
Elevate a mucosal flap to avoid mucosal bleeding when opening the cochlea.	
Begin drilling near the cochlea use a slowly turning diamond drill to avoid acoustic trauma.	
To enter the middle portion of the scala tympani and to get visualization of the round window membrane, the posterior-superior lip of the round window niche and the inferior margin of the round window should be drilled away to expose the round window membrane at least 0.8 mm.	The cochleostomy should be drilled inferior and slightly anterior to the round window annulus to achieve a scala tympani insertion and to avoid damage to the osseous spiral lamina. The endosteum should be exposed to approximately 0.8 mm.
	
Fill the electrode insertion site with corticosteroids.	
Protect the middle ear cavity from bone dust contamination by closing it with medical gauze.	
Drill the implant bed and immobilise the implant.	
Prior to opening the cochlea, clean the surgical field, change gloves, remove the gauze used to keep bone dust out of the middle ear cavity.	
Place a drop of corticosteroid on the round window membrane or endosteum to reduce fibrotic reaction and cover it with a drop of hyaluronic acid. This will keep the corticosteroid in place and protect it from bone dust.	

Figure 77 Hearing Preservation Surgical Technique (Part 1)








Round Window Insertion	Cochleostomy Insertion
Using a micro-lancette or micro-hook, carefully incise the round window membrane in its inferior-anterior quadrant to approximately 0.8 mm.	With a micro-lancette or micro-hook, carefully incise the endosteum to approximately 0.8 mm.
	
Avoid suctioning in the open region of the cochlea.	
Immediately start the electrode insertion through the drop of corticosteroid and hyaluronic acid.	
General insertion direction is from superior-posterior to anterior-inferior with the knob indicating the direction of the apical electrodes facing towards the modiolus.	
<div><ul style="list-style-type: none"><li>1 19 platinum electrode contacts Optimal spacing over a 20.9mm stimulation range</li><li>2 Flex tip for minimal insertion trauma Dimensions at apical end: 0.5 x 0.3mm</li><li>3 Diameter at basal end: 0.8mm</li></ul><p>Insert the FLEX24 electrode so that it covers less than 1.5 turns of the cochlea (22-24mm, determined by pre-operative CT scan).</p></div>	
To seal the cochlea, use a small fascial graft. To prevent contamination of the electrode and to increase flexibility, rinse the fascial graft with saline solution.	
A course of steroids and antibiotics should be given postoperatively.	

Figure 78 Hearing Preservation Surgical Technique (Part 2)

## Literature

The following is a list of references on general CI surgery:

**Evaluation of a minimally invasive surgical fixation technique for young children with the Concerto Pin cochlear implant system.**

Schnabl J; Wolf-Magele A; Pok SM; Url C; Zorowka P; Sprinzl G  
Eur Arch Otorhinolaryngol , 2014 Mar 23

**The Effects of Insertion Speed on Inner Ear Function during Cochlear Implantation: A Comparison Study**

Rajan GP; Kontorinis G; Kuthubutheen J; Audiol Neurotol, 18(1), 2012 Sep 22, p. 17–22

**Synchrony Pin: A Novel Concept of Cochlear Implant Fixation.**

Schnabl J; Markl A; Hormann R; Wolf-Magele A; Scharfetter V; Sprinzl G; Otol Neurotol, 2012.

**Depth of Electrode Insertion and Postoperative Performance in Humans with Cochlear Implants: A Histopathologic Study.**

Lee J; Nadol JB; Eddington DK; Audiol Neurotol, 15(5), 2010, 323–331.

**Cochlear implantation in inner ear malformations**

Sennaroglu L; Cochlear Implants Int, 2009.

**Scala tympani cochleostomy I: results of a survey.**

Adunka OF; Buchman CA; Laryngoscope 2007; 117(12):2187–2194.

**Cochlear implant electrode insertion: The round window revisited.**

Roland P; Wright C; Isaacson B; Laryngoscope 2007; 117(8):1397–402.

**Scala tympani cochleostomy II: Topography and histology.**

Adunka O; Radeloff A; Gstoettner W; Pillsbury H; Buchman C; Laryngoscope 2007; XX:1–6.

**Preservation of basal inner ear structures in cochlear implantation.**

Adunka O; Gstoettner W; Hambek M; Unkelbach MH; Radeloff A; Kiefer J; ORL J Otorhinolaryngol Relat Spec. 2004; 66(6):306–12.

**Cochlear implantation via the round window membrane minimizes trauma to cochlear structures: A histologically controlled insertion study.**

Adunka O; Unkelbach MH; Mack M; Hambek M; Gstoettner W and Kiefer J; Acta Otolaryngol 2004; 124: 807–812.

**J. Müller, F. Schön, J. Helms: Safe fixation of mounts for cochlear implant electrodes initial experience with a new titanium clip.**

Laryngo-Rhino-Otol 1998;77:238–240.

**The length of the organ of Corti in man.**

Hardy M; American Journal of Anatomy, 62(2), 1938, 179–311.

The following is a list of references on bilateral CI surgery:

**Assessment of electrode placement and audiological outcomes in bilateral cochlear implantation.**

Wanna GB, Noble JH, McRackan TR, Dawant BM, Dietrich MS, Watkins LD, Rivas A, Schuman TA, Labadie RF; Otol Neurotol. 2011 Apr.

**Binaural cochlear implantation after bilateral temporal bone fractures.**

Zanetti D, Campovecchi CB, Pasini S.; Int J Audiol. 2010 Jul 8.

**Bilateral cochlear implantation in a patient with bilateral temporal bone fractures.**

Chung JH, Shin MC, Min HJ, Park CW, Lee SH.; Am J Otolaryngol. 2010 May 3.

**Bilateral cochlear implantation in children with anomalous cochleovestibular anatomy**

Chadha NK; James AL; Gordon KA; Blaser S; Papsin BC.; Arch Otolaryngol Head Neck Surg, 135(9), 2009 Sep.

**Bilateral, simultaneous cochlear implantation in children: surgical considerations.**

Migirov, L. & Kronenberg, J.; J Laryngol Otol. 2009 Mar 3:1-3.

**Otopathological Findings in a Patients with Bilateral Cochlear Implants.**

House, W., Johnsson, L. & Linthicum, F.; USPHS Research, 74, 2006.

**Cochlear implantation in a patient with bilateral temporal bone fractures.**

Simons, J., Whitaker, M. & Hirsch, B.; Otolaryngol Head Neck Surg, 132, 809-811; 2005.

**Bilateral cochlear implantation.**

Lustig, L. & Wackym, P.; Operative Techniques in Otolaryngology, 16, 2005.

**Insertion depth differences in bilateral cochlear implantees**

Fielden C; Long C; Cooper H; Proops D; Donaldson I; Craddock L.; Cochlear Implants Int, 6 Suppl 1, 2005 Sep.

**The following is a list of references on HP and EAS:**

**Hearing preservation after cochlear reimplantation**

Helbig S; Rajan GP; Stover T; Lockley M; Kuthubutheen J; Green KM; Otol Neurotol , 34(1), 2013 Jan, p. 61-65

**The Round Window: Is it the "Cochleostomy" of Choice? Experience in 130 Consecutive Cochlear Implants.**

Gudis DA, Montes M, Bigelow DC, Ruckenstein MJ.; Otol Neurotol. 2012 Sep 11.

**Evaluation of round window accessibility to cochlear implant insertion.**

Leong AC, Jiang D, Agger A, Fitzgerald-O'Connor A.; Eur Arch Otorhinolaryngol. 2012 Jul 18.

**Hearing preservation after cochlear implantation using deeply inserted flex atraumatic electrode arrays.**

Tamir S, Ferrary E, Borel S, Sterkers O, Bozorg Grayeli A.; Audiol Neurotol. 2012;17(5):331-7.

**Hearing preservation and hearing improvement after reimplantation of pediatric and adult patients with partial deafness: a retrospective case series review.**

Jayawardena J, Kuthubutheen J, Rajan G.; Otol Neurotol. 2012 Jul;33(5):740-4.

**Scalar localization by computed tomography of cochlear implant electrode carriers designed for deep insertion.**

Helbig S, Mack M, Schell B, Bratzke H, Stöver T, Helbig M.; Otol Neurotol. 2012 Jul;33(5):745-50.

**A case series of paediatric hearing preservation cochlear implantation: a new treatment modality for children with drug-induced or congenital partial deafness.**

Kuthubutheen J, Hedne CN, Krishnaswamy J, Rajan GP.; Audiol Neurotol. 2012;17(5):321-30.

**Cochlear implantation and hearing preservation: Results in 21 consecutively operated patients using the round window approach.**

Erixon E, Köbler S, Rask-Andersen H.; Acta Otolaryngol. 2012.

**Achievement of hearing preservation in the presence of an electrode covering the residual hearing region.**

Usami SI; Moteki H; Suzuki N; Fukuoka H; Miyagawa M; Nishio SY; Takumi Y; Iwasaki S; Jolly C; Acta Otolaryngol, 2011.

**Combined electric acoustic stimulation with the PULSARCI(100) implant system using the FLEX(EAS) electrode array.**

Helbig S; Van de Heyning P; Kiefer J; Baumann U; Kleine-Punte A; Brockmeier H; Anderson I; Gstoettner W; Acta Otolaryngol, 2011.

**Atraumatic round window deep insertion of cochlear electrodes.**

Skarzynski H; Lorens A; Zgoda M; Piotrowska A; Skarzynski PH; Szkielkowska A.; Acta Otolaryngol , 2011.

**Hearing Preservation After Complete Cochlear Coverage in Cochlear Implantation With the Free-Fitting FLEX<sup>SOFT</sup> Electrode Carrier**

Helbig S; Baumann U; Hey C; Helbig M; Otol Neurotol , 2011 Jul 1

**Is Electric Acoustic Stimulation Better Than Conventional Cochlear Implantation for Speech Perception in Quiet?**

Adunka OF; Pillsbury HC; Adunka MC; Buchman CA; Otol Neurotol, 2010.

**Electric Acoustic Stimulation in Patients with Postlingual Severe High-Frequency Hearing Loss: Clinical Experience.**

Arnoldner C; Helbig S; Wagenblast J; Baumgartner WD; Hamzavi JS; Riss D; Gstoettner W; Adv Otorhinolaryngol, 67, 2010.

**Partial deafness cochlear implantation at the university of kansas: techniques and outcomes.**

Prentiss S; Sykes K; Staecker HJ; Am Acad Audiol, 21(3), 2010.

**Preliminary Results of Electric and Acoustic Stimulation Using the MED-EL Sonata Flex EAS Electrode Array.**

Walker A; Mawman D; Brough J; O'Driscoll M; Ramsden R; Green K; Freeman S; Cochlear Implants Int, 11 (Suppl. 2), 2010.

**Electric Acoustic Stimulation (EAS) of the Auditory System: Experience and Results of Ten Patients Using MED-EL's M and Flex<sup>EAS</sup> Electrodes.**

Lee A; Jiang D; McLaren S; Nunn T; Demler J; Tysome J; Connor S; Fitzgerald O'Connor A; Clinical Otolaryngology, 2010.

**Results of partial deafness cochlear implantation using various electrode designs.**

Skarzynski H; Lorens A; Piotrowska A; Podskarbi-Fayette R; Audiol Neurotol, 14 Suppl 1, 2009.

**Preservation of low frequency hearing in partial deafness cochlear implantation (PDCI) using the round window surgical approach.**

Skarzynski H; Lorens A; Piotrowska A; Anderson I; Acta Otolaryngol 2007; 127(1): 41-8.

**Outcomes in adults implanted with the FLEX<sup>soft</sup> electrode.**

Baumgartner W; Jappel A; Morera Perez C; Gstöttner W; Müller J; Kiefer J; Van De Heyning P; Anderson I; Bryde Nielsen S.; Acta Otolaryngol , 127(579), 2007.

**Method for hearing preservation in cochlear implant surgery.**

Roland P; Gstoettner W; Adunka O.; Otolaryngol 2005; 16: 93-100.

**Conservation of low-frequency hearing in cochlear implantation.**

Kiefer J et al.; Acta Otolaryngol 2004; 124: 272-280.

**The following is a list of references on young children:**

**Functional outcome of sequential bilateral cochlear implantation in young children: 36 months postoperative results**

Scherf FW; Van DL; van WA; Wouters J; Desloovere C; Dhooge I; Offeciers E; Deggouj N; De RL; De BM; Van de Heyning PH; Int J Pediatr Otorhinolaryngol , 2009 Feb 26

**Ear Surgery in Infants Under One Year of Age: Its Risks and Implications for Cochlear Implant Surgery**

Johr M; Ho A; Wagner CS; Linder T; Otol Neurotol, 29(3), 2008 Apr, p. 310-313

**Surgical Factors in Pediatric Cochlear Implantation and Their Early Effects on Electrode Activation and Functional Outcomes**

Francis HW; Buchman CA; Visaya JM; Wang NY; Zwolan TA; Fink NE; Niparko JK; Otol Neurotol , 2008 Apr 4

**Hearing benefits of second-side cochlear implantation in two groups of children**

Scherf F.; van Deun L.; van Wieringen A.; Wouters J.; Desloovere C.; Dhooge I.; Offeciers E.; Deggouj N.; De Raeve L.; De Bodt M.; Van De Heyning P.; Int J Pediatr Otorhinolaryngol, 71(12), 2007 Dec, p. 1855-1863

**Simultaneous versus sequential bilateral implantation in young children: Effects on central auditory system development and plasticity**

Sharma A.; Gilley P.; Martin K.; Roland P.; Bauer P.; Dorman M.;  
Audiological Medicine, 5(4), 2007, p. 218–223

**Complications in children with long-term cochlear implants**

Lin Y.; Lee F.; Peng S.; ORL J Otorhinolaryngol Relat Spec, 68(4),  
2006, p. 237–242

**Cochlear implantation in children younger than 12 months of age**

Wackym P.; Firszt J.; Runge-Samuelson C; Operative Techniques in  
Otolaryngology, 16, 2005, p. 101–106

**Cochlear implantation in deaf infants**

Miyamoto R.; Houston D; Bergeson T; Laryngoscope, 115, 2005,  
p. 1376–1380

**Cochlear implantation at under 12 months: Report on 10 patients**

Colletti V; Carner M; Miorelli V; Guida M; Colletti L; Fiorino F;  
Laryngoscope, 115, 2005, p. 445–449

**The following is a list of references on alternative approaches:**

**VERIA TECHNIQUE**

**Veria operation: Updated.**

Kiratzidis T, Arnold W, Iliades T.; ORL 64:406–412, 2002.

**Veria operation.**

Kiratzidis T, Iliades T, Arnold W.; ORL 64:413–416, 2002.

**Veria operation: Cochlear implantation without a mastoidectomy and a posterior tympanotomy.**

Kiratzidis T.; Adv Otorhinolaryngol 57:127–130, 2000.

**SUPRAMEATAL APPROACH**

**How we do it? The suprameatal approach – An alternative surgical technique for cochlear implantation.**

Kronenberg J; Migirov L.; Cochlear Implants International 7:142–  
147, 2006.

**The Suprameatal Approach: An alternative surgical approach to cochlear implantation.**

Kronenberg J; Baumgartner W; Migirov L; Dagan T; Hildesheimer M.; Otol Neurotol 25:41–45, 2004.

**The role of Mastoidectomy in cochlear implant surgery.**

Kronenberg J; Migirov L.; Acta Otolaryngol 123:219–222, 2003.

**The suprameatal approach in cochlear implant surgery: Our experience with 80 patients.**

Kronenberg J; Migirov L; Baumgartner W.; ORL 64:403–405,  
2002.

**Suprameatal approach. New surgical approach for cochlear implantation.**

Kronenberg J; Migirov L; Dagan T; J.Laryngol Otol 115:283–285,  
2001.

**PERI CANAL TECHNIQUE**

**Cochlear implantation without mastoidectomy: The pericanal electrode insertion technique.**

Häusler R; Acta Oto-Laryngologica 122:715–719, 2002.

**ATTICOTOMY APPROACH**

**Transeptomypanic Approach in Cochlear Implantation.**

Nahler A; Böheim K; 5th European Congress of Oto-Rhino-  
Laryngology Head and Neck Surgery, Rodos-Kos Hellas 2004.  
(Poster)

**Kombinierter Epitympanaler – Transmeataler Zugang bei Cochleaimplantation.**

Nahler A; Böheim K; 47. Österreichischer HNO-Kongreß 2003. (in  
German)

**Transatrical Approach Modifications.**

Cózar; Fragola; Calderón; Revilla; González de Ubieta;  
Poster presentation Las Palmas 2002. (Poster),  
Arauz: <http://www.implantescocleares.com/> (in Spanish, with  
video).



MED-EL Elektromedizinische Geräte GmbH  
Worldwide Headquarters  
Fürstenweg 77a  
6020 Innsbruck, Austria  
[office@medel.com](mailto:office@medel.com)

[medel.com](https://www.medel.com)

